التهاب الجنب
Pleuritis

Pleuritis

- **irritation of the parietal pleura→ Pleural Pain**
- **pain is localized ,sharp, and it is made worse by coughing, sneezing, deep breathing, or movement .**
- **central portion of the diaphragmatic parietal pleura is irritated, pain may be referred to the ipsilateral shoulder.**
- **In young, pleuritis is usually caused by viral respiratory infections or pneumonia.**

أسباب التهاب الجنب

- ذوات الجنب الانتانية
- خراجات الرئة
- احتشاء الرئة
- التدرن
- الذئبة الحمامية الجهازية & الداء الرثواني

Treatment of pleuritis

- treating the underlying disease.
- Analgesics and anti-inflammatory drugs
- Codeine may be used to control cough
- Intercostal nerve blocks are sometimes helpful

Pleural Effusion
انصبابات الجنب

- May be asymptomatic
- dyspnea is common with large effusions.
- Dullness to percussion and decreased breath sounds over the effusion.
- Radiographic evidence of pleural effusion.
- Diagnostic findings on thoracentesis

General Considerations

- Absorption of pleural fluid occurs through parietal pleural lymphatics.
- 5–15 mL of fluid in the normal pleural space.
- A pleural effusion is an abnormal accumulation of fluid in the pleural space.
- Diagnostic thoracentesis should be performed whenever there is a new pleural effusion

Physiology of the Pleural Space

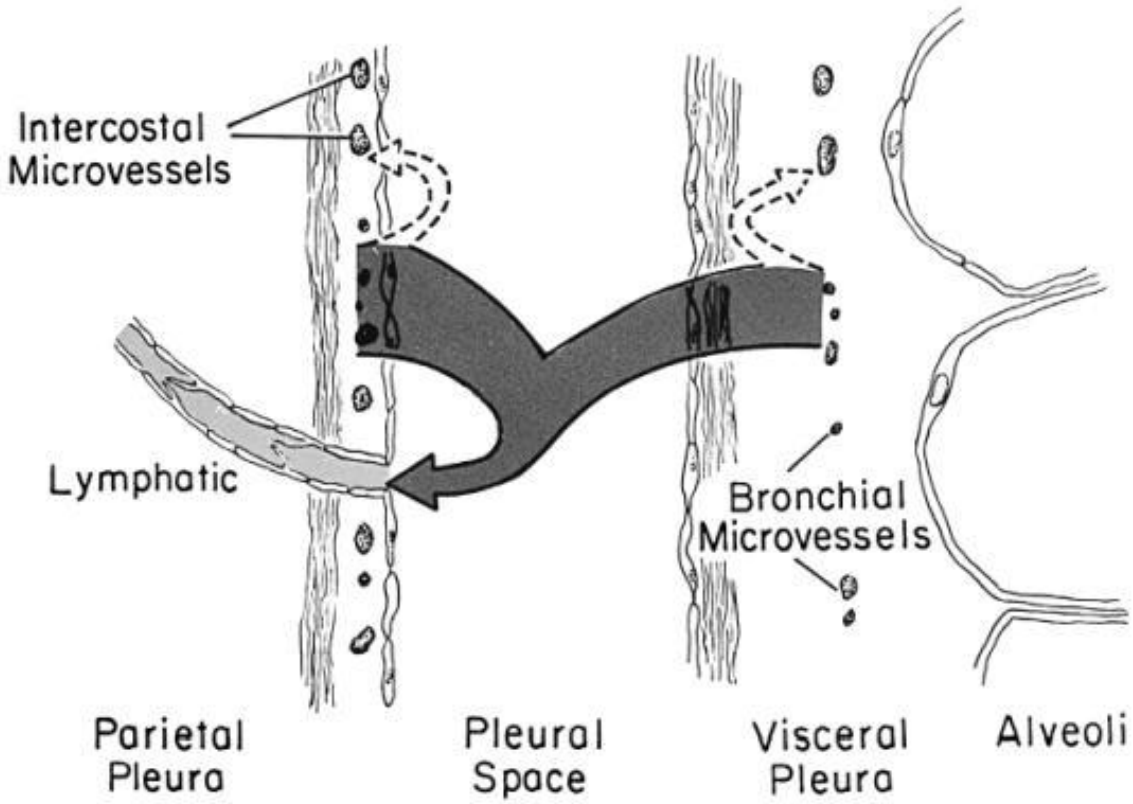

From: Cretien, J, Bignon, J., Hirsch, A, eds: The Pleura in Health and Disease.
New York: Marcel Dekker, 1985, p182.

Technique of thoracentesis
تقنية البزل الاستقصائي للجنب

Technique of thoracentesis
تقنية البزل الاستقصائي للجنب

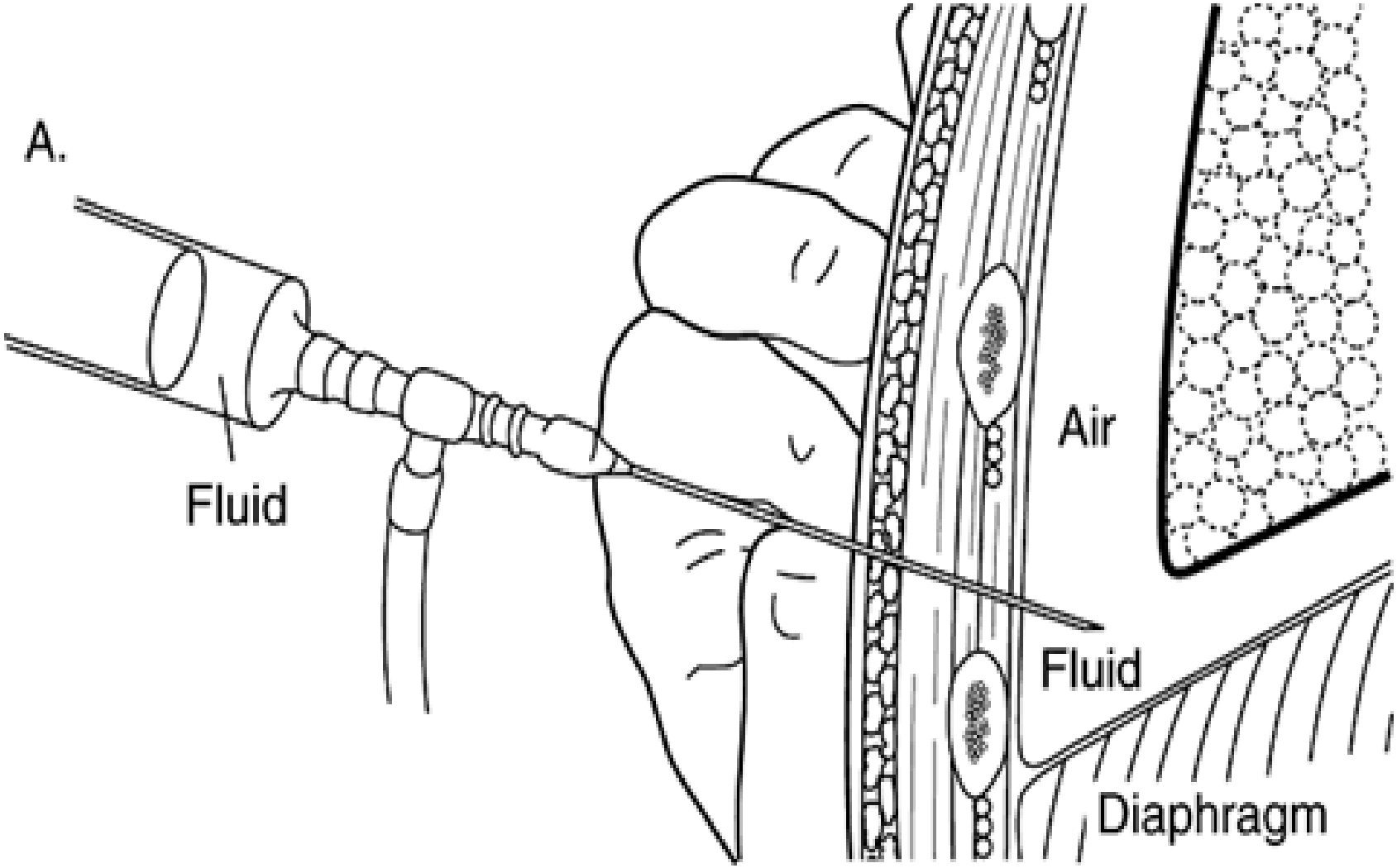

Technique of thoracentesis
تقنية البزل الاستقصائي للجنب

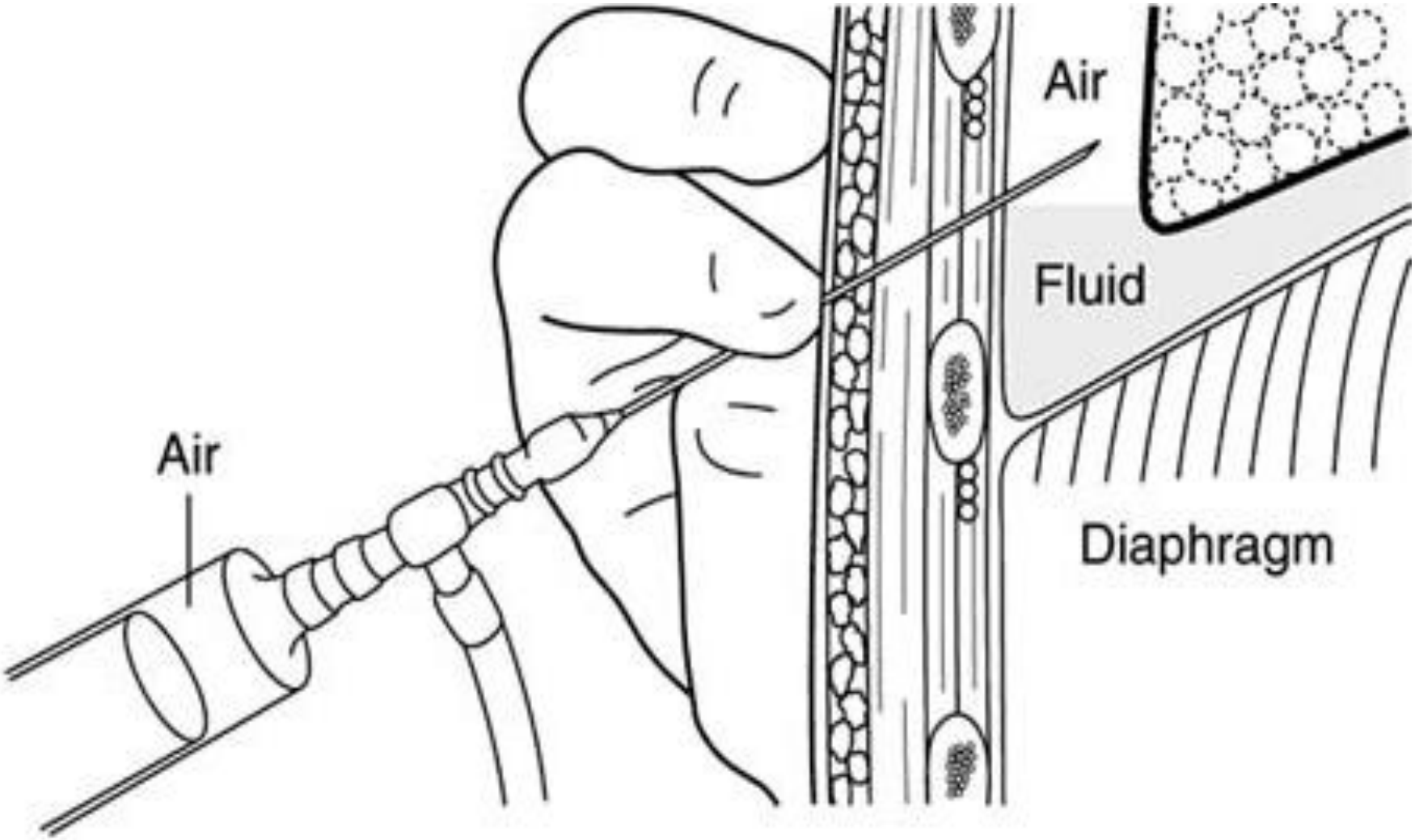

وضعية خاطئة لبزل الجنب

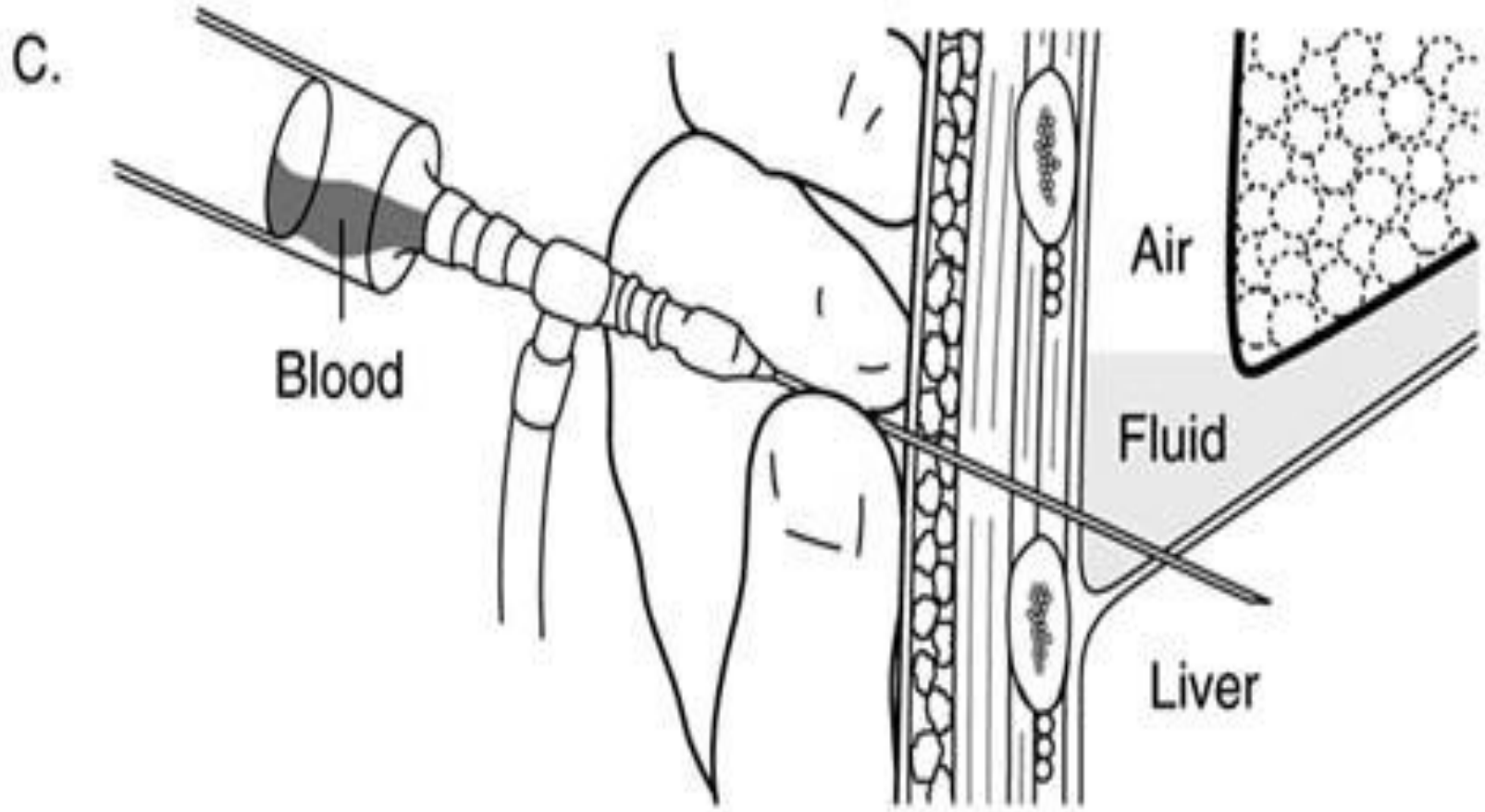

بزل إفراغي للجنب

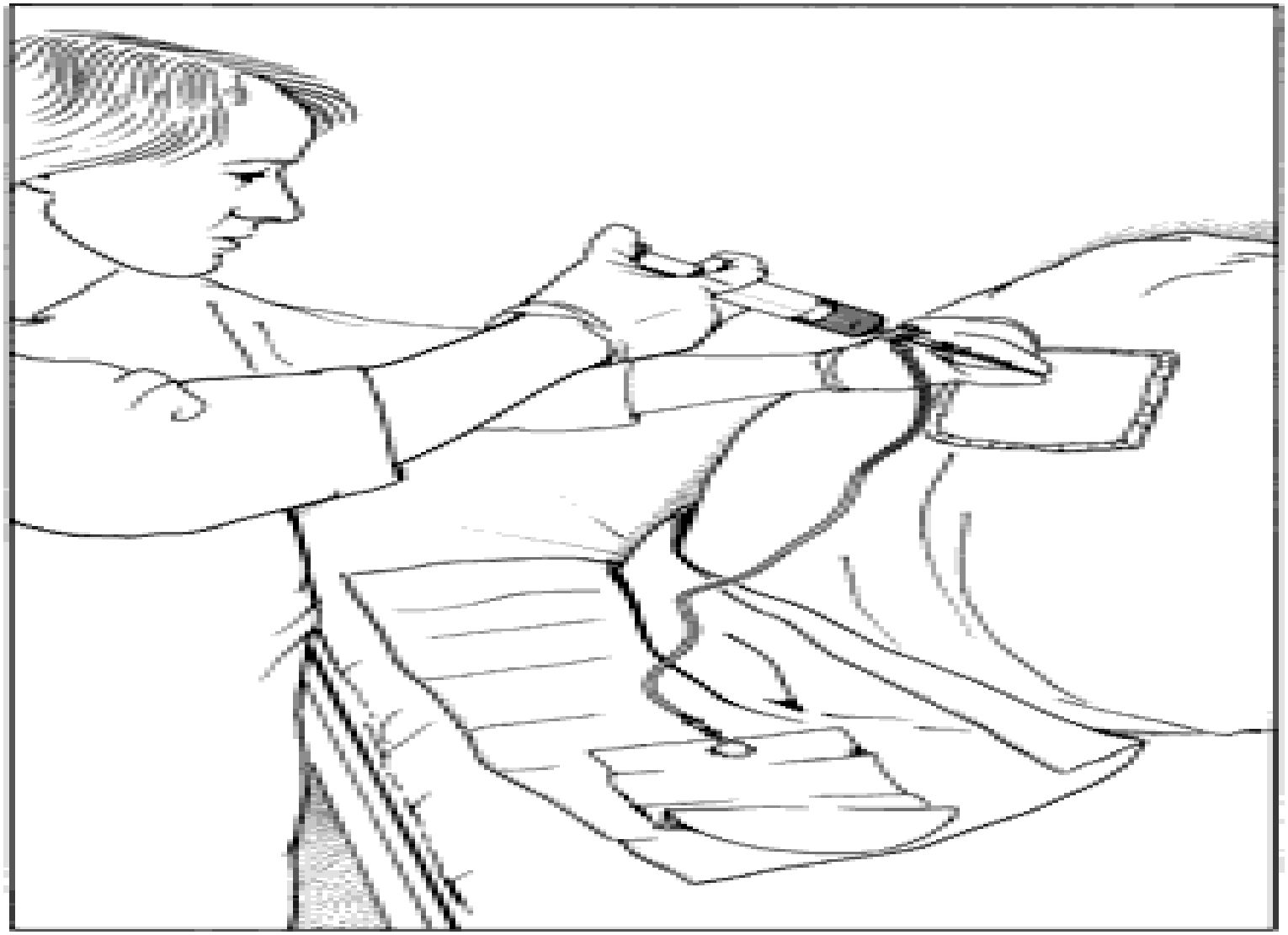

اختلاطات البزل الاستقصائي

- صدمة ألمية
- وذمة رئوية
- ريح صدرية
- تقيح جنب

pathophysiologic processes
الآليات الفيزيولوجية المرضية

- Increased hydrostatic or decreased oncotic pressures (transudates)
- increased production of fluid due to abnormal capillary permeability (exudates)
- decreased lymphatic clearance of fluid from the pleural space (exudates)
- infection in the pleural space (empyema)
- bleeding into the pleural space (hemothorax).

Transudate :

- Due to hydrostatic / colloid pressure imbalance (CHF, cirrhosis, nephrosis
- Pleura usually intact

(protein content low - specific gravity <1.012)

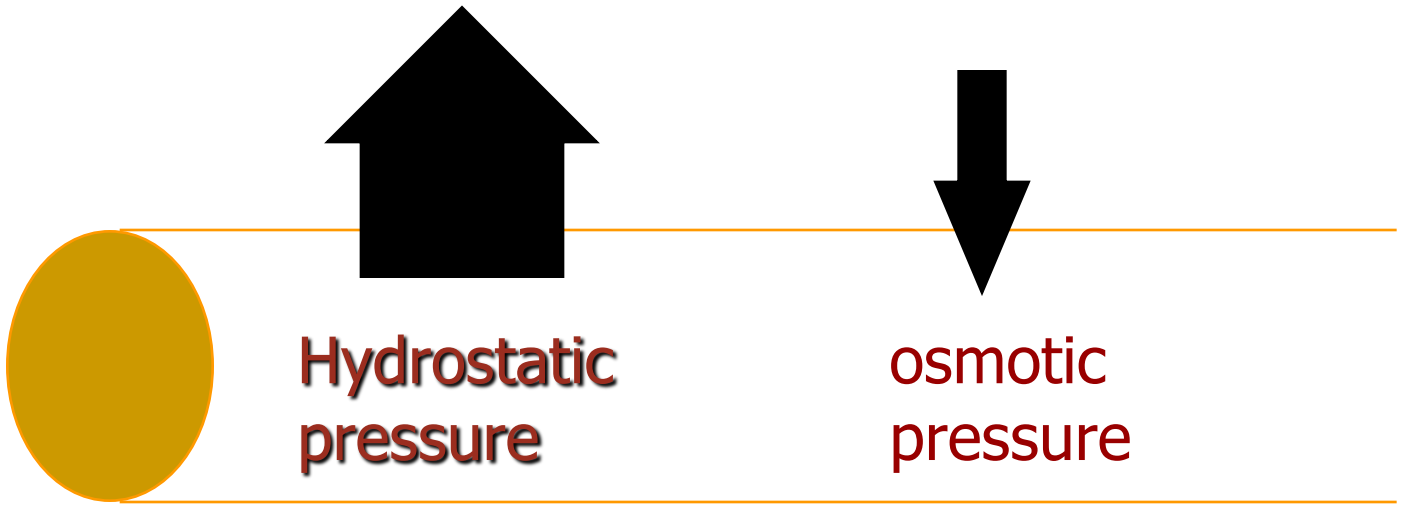

Exudate:

- Due to inflammation / disease of pleura
- Pneumonia, malignancy.

(protein content high - specific gravity >1.020)

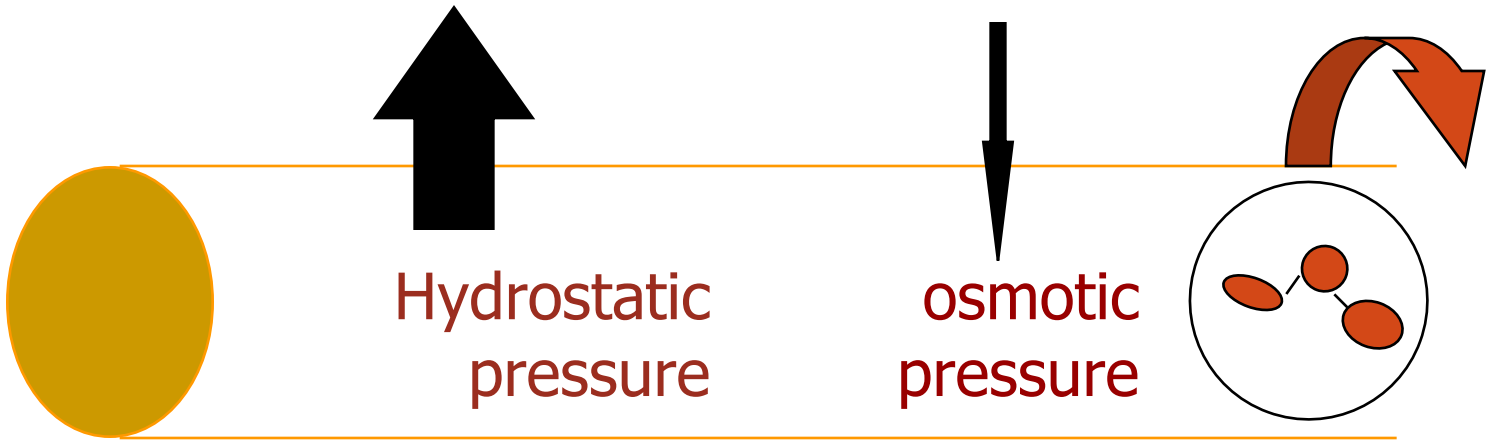

Diapedesis

Causes of pleural effusion

Common causes

- Pneumonia ('para-pneumonic effusion')
- Tuberculosis
- Pulmonary infarction*
- Malignant disease
- Cardiac failure*
- Subdiaphragmatic disorders (subphrenic abscess, pancreatitis etc.)

Uncommon causes

- Hypoproteinaemia* (nephrotic syndrome, liver failure, malnutrition)
- Connective tissue diseases* (particularly systemic lupus erythematosus (SLE) and rheumatoid arthritis)
- Acute rheumatic fever
- Post-myocardial infarction syndrome
- Meigs' syndrome (ovarian tumour plus pleural effusion)
- Myxoedema*
- Uraemia*
- Asbestos-related benign pleural effusion

Causes of pleural fluid transudates and exudates.

Transudates	Exudates
Congestive heart failure (≈90% of cases)	Pneumonia (parapneumonic effusion)
Cirrhosis with ascites	Cancer
Nephrotic syndrome	Pulmonary embolism
Peritoneal dialysis	Bacterial infection
Myxedema	Tuberculosis
Acute atelectasis	Connective tissue disease
Constrictive pericarditis	Viral infection
Superior vena cava obstruction	Fungal infection
Pulmonary embolism	Rickettsial infection
	Parasitic infection
	Asbestos
	Meigs' syndrome
	Pancreatic disease
	Uremia
	Chronic atelectasis
	Trapped lung
	Chylothorax
	Sarcoidosis
	Drug reaction
	Post-myocardial infarction syndrome

Clinical Findings
الموجودات السريرية

- most often report dyspnea, cough, or respirophasic chest pain.
- Small pleural effusions are less likely to be symptomatic than larger effusions.
- Physical findings are usually absent in small effusions.
- dullness to percussion and diminished or absent breath sounds over the effusion
- bronchial breath sounds and egophony just above the effusion.
- A massive effusion → contralateral shift of the trachea .
- A pleural friction rub indicates infarction or pleuritis .

Laboratory Findings
الموجودات المخبرية

- **Appearance : * Grossly purulent fluid signifies empyema**
  *** persistently turbid supernatant suggests a chylous effusion. chylomicrons and a high triglyceride level (> 100 mg/dL)**
  *** Hemorrhagic pleural effusion : 10000 red cells per milliliter create blood-tinged pleural fluid; 100,000/mL create grossly bloody pleural fluid.**

Observations of pleural fluid helpful in diagnosis

	Suggested diagnosis
Color of fluid	
Pale yellow (straw)	Transudate, some exudates
Red (bloody)	Malignancy, benign asbestos pleural effusion, postcardiac injury syndrome, or pulmonary infarction in absence of trauma
White (milky)	Chylothorax or cholesterol effusion
Brown	Long-standing bloody effusion; rupture of amebic liver abscess
Black	Aspergillus
Yellow-green	Rheumatoid pleurisy
Dark green	Biliothorax
Color of:	
Enteral tube feeding	Feeding tube has entered pleural space
Central venous catheter infusate	Extravascular catheter migration
Character of fluid	
Pus	Empyema
Viscous	Mesothelioma
Debris	Rheumatoid pleurisy
Turbid	Inflammatory exudate or lipid effusion
Anchovy paste	Amebic liver abscess

analyze fluid for

- protein, LDH: transudate vs exudate
- gram stain, Ziehl-Neilsen stain (TB), culture
- cell count and differential: neutrophils vs. lymphocytes
- lymphocytic : TB, lymphoma
- cytology: malignancy, infection
- low glucose: RA, TB, empyema, malignancy
- rheumatoid factor, ANA, complement
- amylase: pancreatitis, esophageal perforation
- pH: empyema < 7.2; TB and mesothelioma < 7.3
- blood: mostly traumatic, malignancy, PE with infarction, TB
- TG: chylothorax from thoracic duct leakage, mostly due to trauma, lung CA, lymphoma

amylase-rich pleural effusion

- • Acute pancreatitis
- • Chronic pancreatic pleural effusion
- • Esophageal rupture
- • Malignancy

Lymphocytosis

- tuberculous pleurisy
- lymphoma
- sarcoidosis
- chronic rheumatoid pleurisy
- yellow nail syndrome
- chylothorax
- Carcinomatous pleural effusions

Eosinophilia : more than 10 percent of the total nucleated cells

- Pneumothorax
- Hemothorax
- Pulmonary infarction
- Benign asbestos pleural effusion
- Parasitic disease
- Fungal infection (coccidioidomycosis, cryptococcosis, histoplasmosis)
- Drugs
- Malignancy (carcinoma, lymphoma)

تكيلس الصدر (الإنصباب الكيلوسي) Chylothorax

- انصباب جنبي غزير ، زلة
- TG > 110 ملغ / د. ل
- العلاج :
  مجازة جنبية بريتوانية
  تفجير صدر ؟

Chylothorax

- Leakage of lymph
- TG > 110mg/ dl or chylomicrons in fluid
- Usually a result of surgical trauma during mediastinal procedures
- Traumatic vs nontraumatic
- Traumatic: 2/3, unilateral
- Nontraumatic: 1/3, bilateral, assoc. with SVC thrombosis (Tumor - lymphoma, lymhangiomyomatosis)

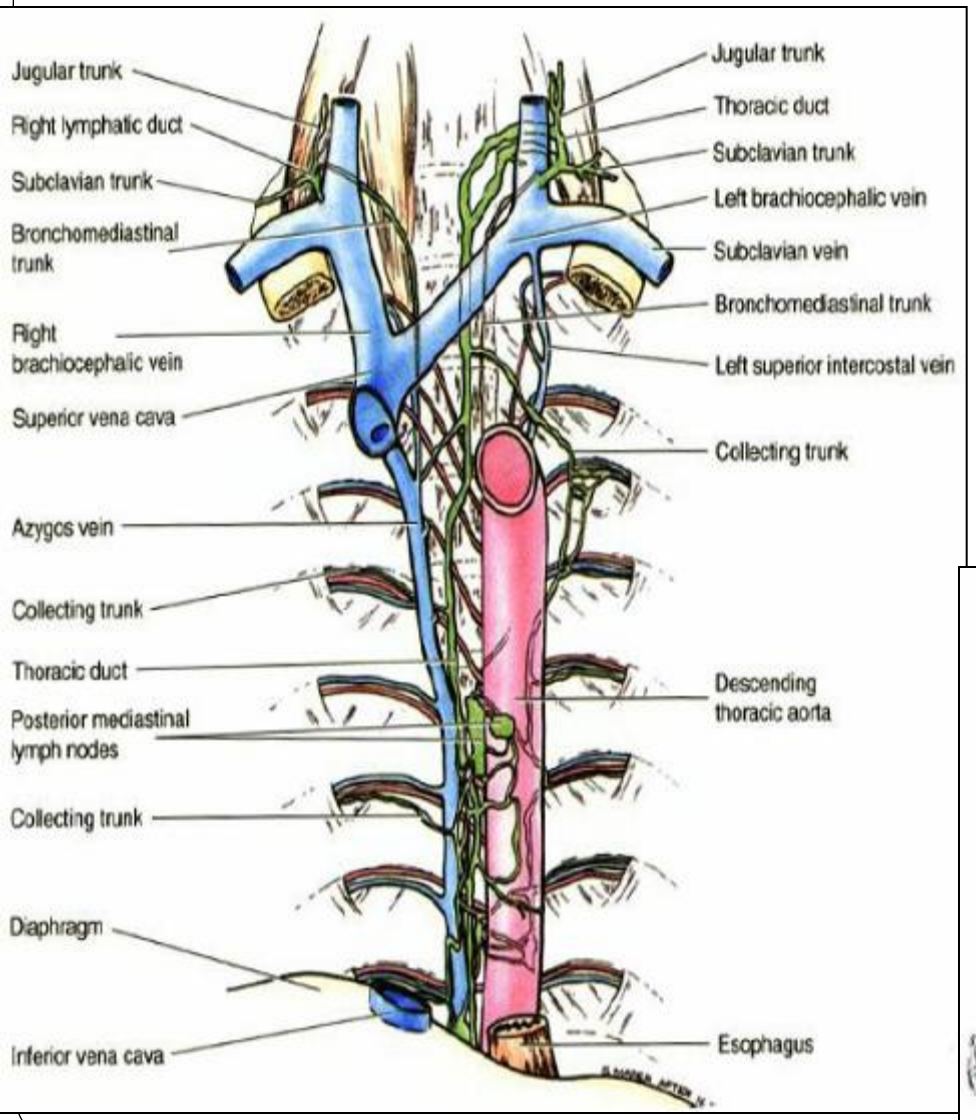

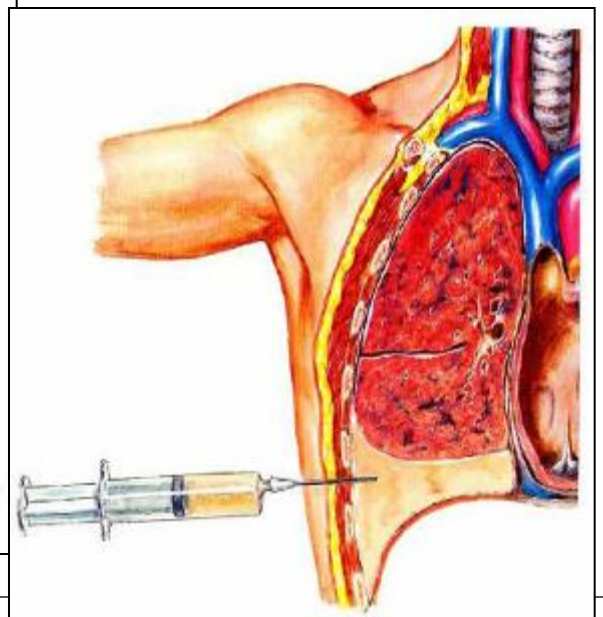

cholesterol effusion (a pseudochylothorax or chyliform effusion)

- elevated cholesterol concentrations greater than 250 mg/dL and a triglyceride concentration below 110 mg/dL.
- Chylomicrons are not present in a cholesterol pleural effusion.
- occurs in patients with thickened and sometimes calcified pleural surfaces in the setting of a chronic pleural effusion, usually of five years duration

Laboratory Findings
الموجودات المخبرية

- **Hemothorax : presence of gross blood in the pleural space , defined as a ratio of pleural fluid hematocrit to peripheral blood hematocrit > 0.5.**
- **measurement of protein, glucose, LDH , total and differential white blood cell counts.**
- **A pleural exudate is an effusion that has *one or more of the following laboratory* features:**
  (1) ratio of pleural fluid protein to serum protein > 0.5
  (2) ratio of pleural fluid LDH to serum LDH > 0.6
  (3) pleural fluid LDH greater than two-thirds the upper limit of normal serum LDH.

Hemothorax

- Defined as pleural fluid hematocrit of 50% of blood hematocrit
- Will coagulate & may lead to loculation with complications of fibrothorax & posible empyema
- If small, may defibrinate & remain free flowing

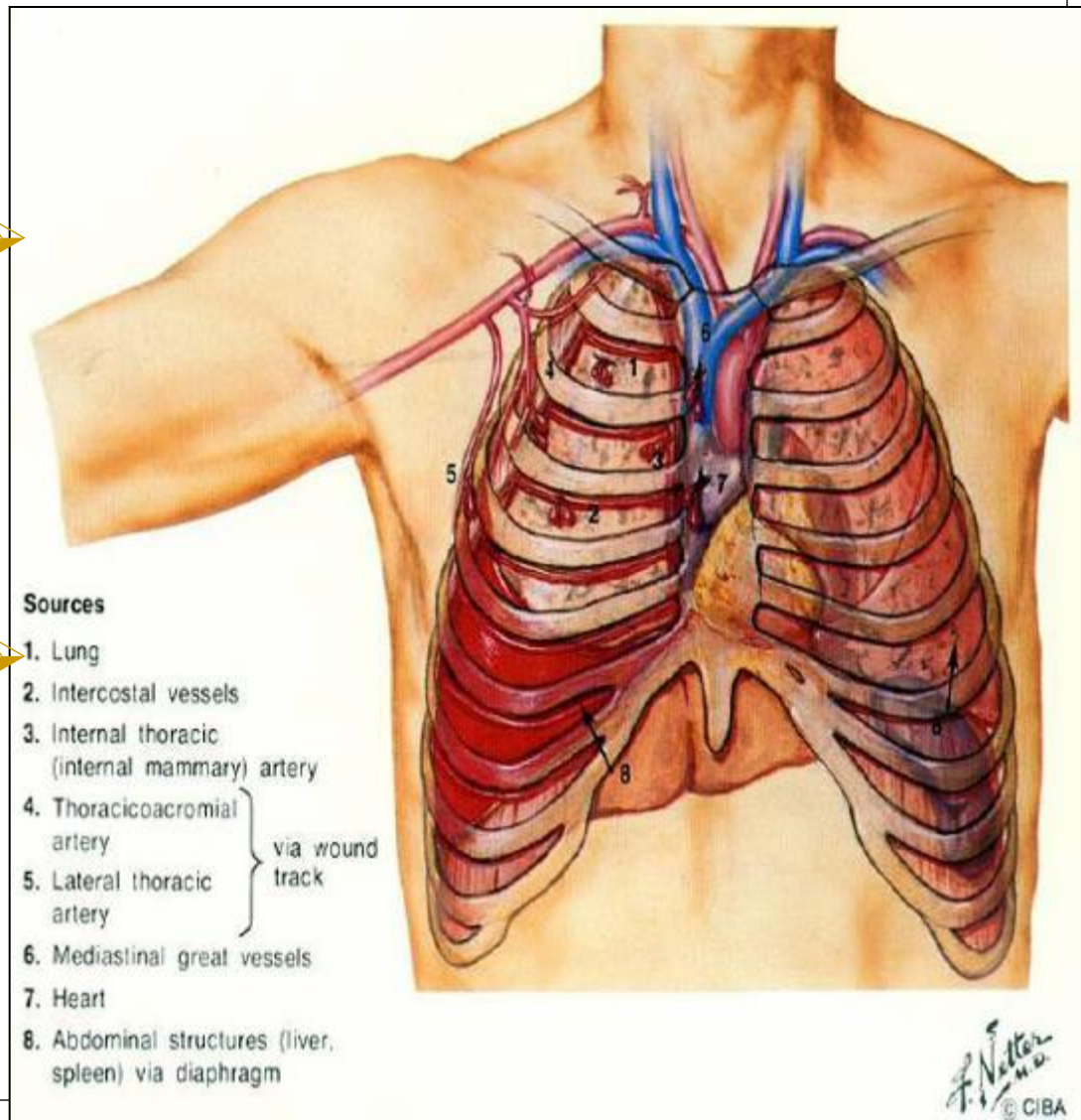

A pleural exudate
معايير الانصباب النتحي

- • Two-test rule :
  - Pleural fluid cholesterol greater than 45 mg/dL
  - Pleural fluid LDH greater than 0.45 times the upper limit of the laboratory's normal serum LDH

- • Three-test rule :
  - Pleural fluid protein greater than 2.9 g/dL (29 g/L)
  - Pleural fluid cholesterol greater than cholesterol 45 mg/dL (1.165 mmol/L)
  - Pleural fluid LDH greater than 0.45 times the upper limit of the laboratory's normal serum LDH

Light's criteria for distinguishing pleural transudate from exudate

Pleural fluid is an exudate if one or more of the following criteria are met:

- Pleural fluid protein:serum protein ratio > 0.5
- Pleural fluid LDH:serum LDH ratio > 0.6
- Pleural fluid LDH > two-thirds of the upper limit of normal serum LDH

Laboratory Findings
الموجودات المخبرية

- **Pleural fluid pH is useful in the assessment of parapneumonic effusion**
- **elevated amylase level in pleural fluid suggests pancreatitis, pancreatic pseudocyst, adenocarcinoma of the lung or pancreas, or esophageal rupture.**
- **culture and pleural biopsy is indicated in suspected tuberculous pleural effusion.(Pleural fluid culture is 44% sensitive , culture and histologic examination for granulomas is 70–90% sensitive)**

Laboratory Findings
الموجودات المخبرية

- cytologic examination : Sensitivity is between 50% and 65%.
- pleural biopsy: for suspected TB, mesothelioma, or other malignancy
- thoracoscopy (by a pulmonologist or by VATS) is preferred to closed pleural biopsy.
- The sensitivity of thoracoscopy is 92–96%.

مضادات استطباب خزعة الجنب

- **عدم وجود سائل في الجنب**
- **اضطراب نزفي**

Diagnoses established "definitively" by pleural fluid analysis

Disease	Diagnostic pleural fluid tests
Empyema	Observation (pus, putrid odor); culture
Malignancy	Positive cytology
Lupus pleuritis	LE cells present; pleural fluid serum ANA >1.0
Tuberculous pleurisy	Positive AFB stain, culture
Esophageal rupture	High salivary amylase, pleural fluid acidosis (often as low as 6.00)
Fungal pleurisy	Positive KOH stain, culture
Chylothorax	Triglycerides (>110 mg/dL); lipoprotein electrophoresis (chylomicrons)
Hemothorax	Hematocrit (pleural fluid/blood >0.5)
Urinothorax	Creatinine (pleural fluid/serum >1.0)
Peritoneal dialysis	Protein (<1 g/dL); glucose (300 to 400 mg/dL)
Extravascular migration of central venous catheter	Observation (milky if lipids are infused); pleural fluid/serum glucose >1.0
Rheumatoid pleurisy	Characteristic cytology

Transudate pleural effusion

- *absence of local pleural diseas*
- **Glucose equal to serum glucose, pH between 7.40 and 7.55, and fewer than 1000 white blood cells/mcL with a predominance of mononuclear cells.**
- **congestive heart failure accounts for 90% of transudates**

Exudate pleural effusion

- increased capillary permeability or reduced lymphatic drainage.
- Bacterial pneumonia and cancer are the most common causes of exudative effusion

Pleural effusion: main causes and features

Cause	Appearance of fluid	Type of fluid	Predominant cells in fluid	Other diagnostic features
Tuberculosis	Serous, usually amber-coloured	Exudate	Lymphocytes (occasionally polymorphs)	Positive tuberculin test Isolation of *M. tuberculosis* from pleural fluid (20%)
				Positive pleural biopsy (80%)
Malignant disease	Serous, often blood-stained	Exudate	Serosal cells and lymphocytes	Positive pleural biopsy (40%) Evidence of malignant disease elsewhere
			Often clumps of malignant cells	
Cardiac failure	Serous, straw-coloured	Transudate	Few serosal cells	Other evidence of left ventricular failure Response to diuretics
Pulmonary infarction	Serous or blood-stained	Exudate (rarely transudate)	Red blood cells Eosinophils	Evidence of pulmonary infarction Source of embolism
				Factors predisposing to venous thrombosis
Rheumatoid disease	Serous Turbid if chronic	Exudate	Lymphocytes (occasionally polymorphs)	Rheumatoid arthritis; rheumatoid factor and anti-CCP antibodies
				Cholesterol in chronic effusion; very low glucose in pleural fluid
SLE	Serous	Exudate	Lymphocytes and serosal cells	Other manifestations of SLE Antinuclear factor or anti-DNA in serum
Acute pancreatitis	Serous or blood-stained	Exudate	No cells predominate	High amylase in pleural fluid (greater than in serum)
Obstruction of thoracic duct	Milky	Chyle	None	Chylomicrons

Imaging
التصوير الشعاعي

- 75–100 mL of pleural fluid must accumulate in the posterior costophrenic sulcus to be visible on the lateral view
- 175–200 mL must be present in the lateral costophrenic sulcus to be visible on the frontal view.
- CXR :
  - dense opacification of lung fields with concave meniscus
  - P/A: blunting of lateral costophrenic angle
  - decubitus: fluid will shift unless is loculated
  - supine: fluid will appear as general haziness
- Chest CT scans may identify as little as 10 mL of fluid.
- Ultrasonography is useful to guide thoracentesis in the setting of smaller effusions.

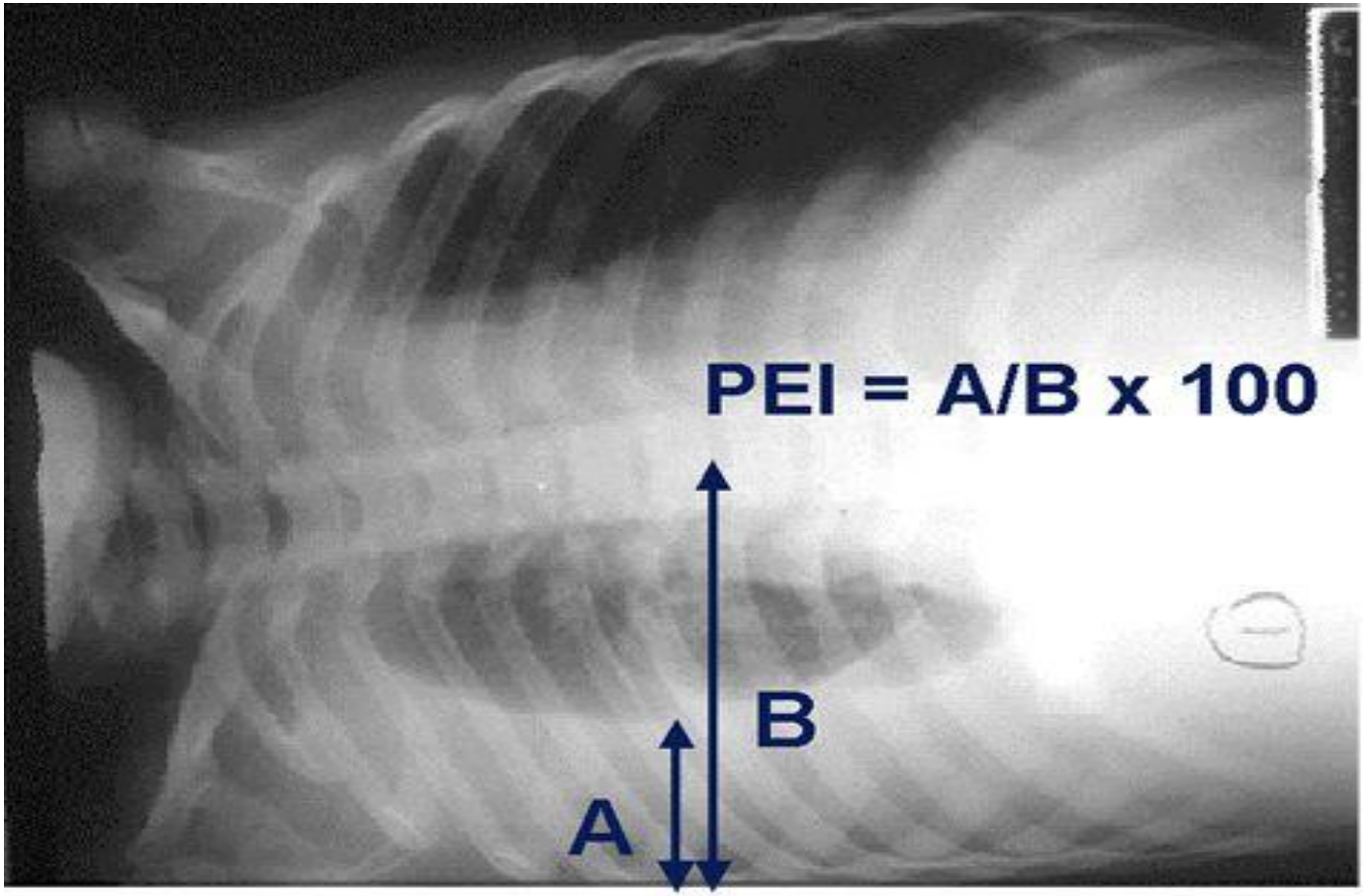
PEI = A/B x 100
B
A

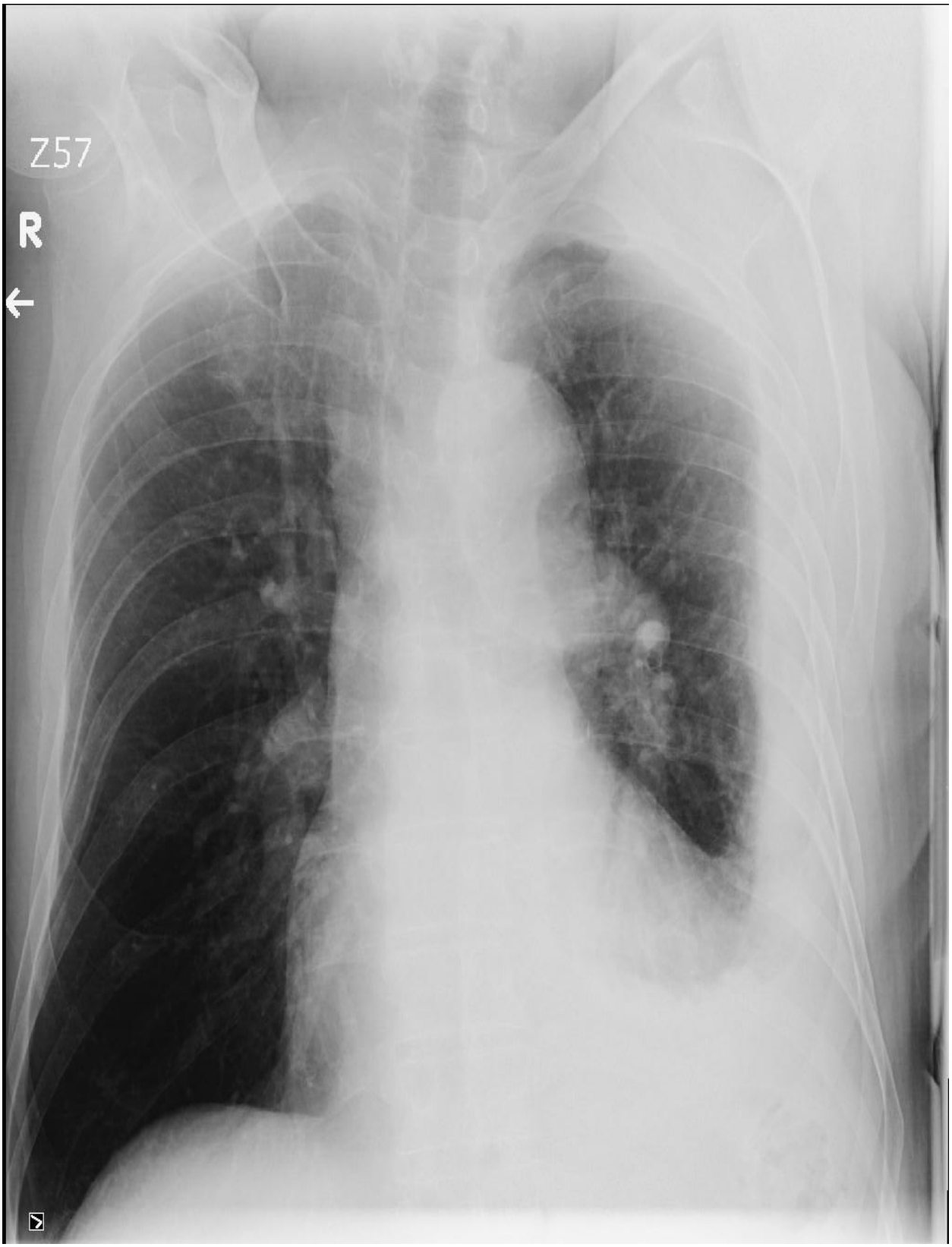
Z57
R

Free layering pleural effusion

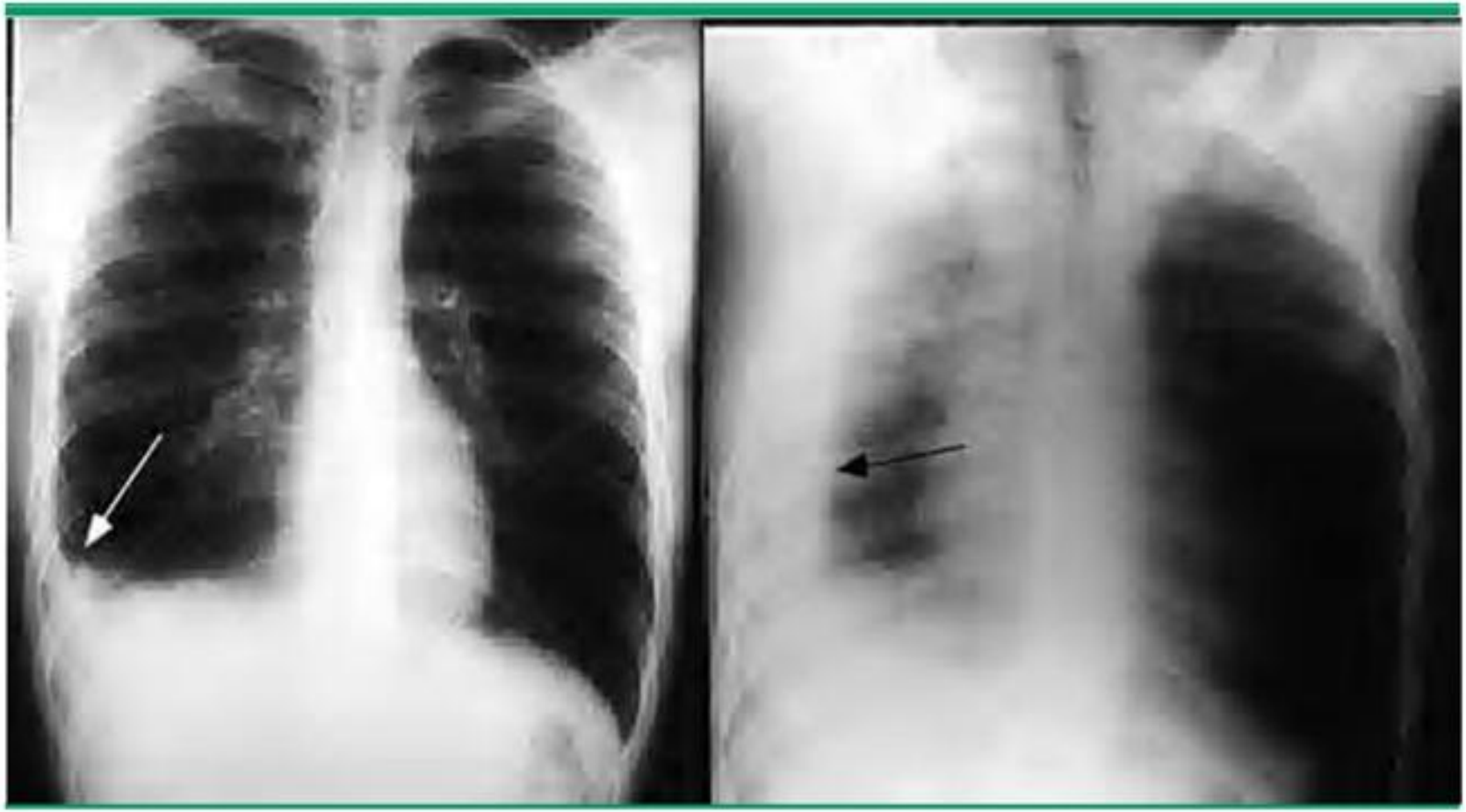

The left panel shows blunting of the right costophrenic sulcus (white arrow) on an upright chest radiograph due to the presence of a pleural effusion. The right panel shows a right lateral decubitus radiograph from the same patient, and reveals layering of pleural effusion (black arrow). Effusions thicker than 1 cm on decubitus views are usually large enough for sampling with thoracentesis.

Right subpulmonic pleural effusion

Chest radiograph of a right subpulmonic pleural effusion. The right lung base is slightly elevated. A small pneumoperitoneum outlines the actual level of the right hemidiaphragm. Left pleural effusion has spilled over into the left lateral costophrenic sulcus.

Subpulmonic pleural effusion

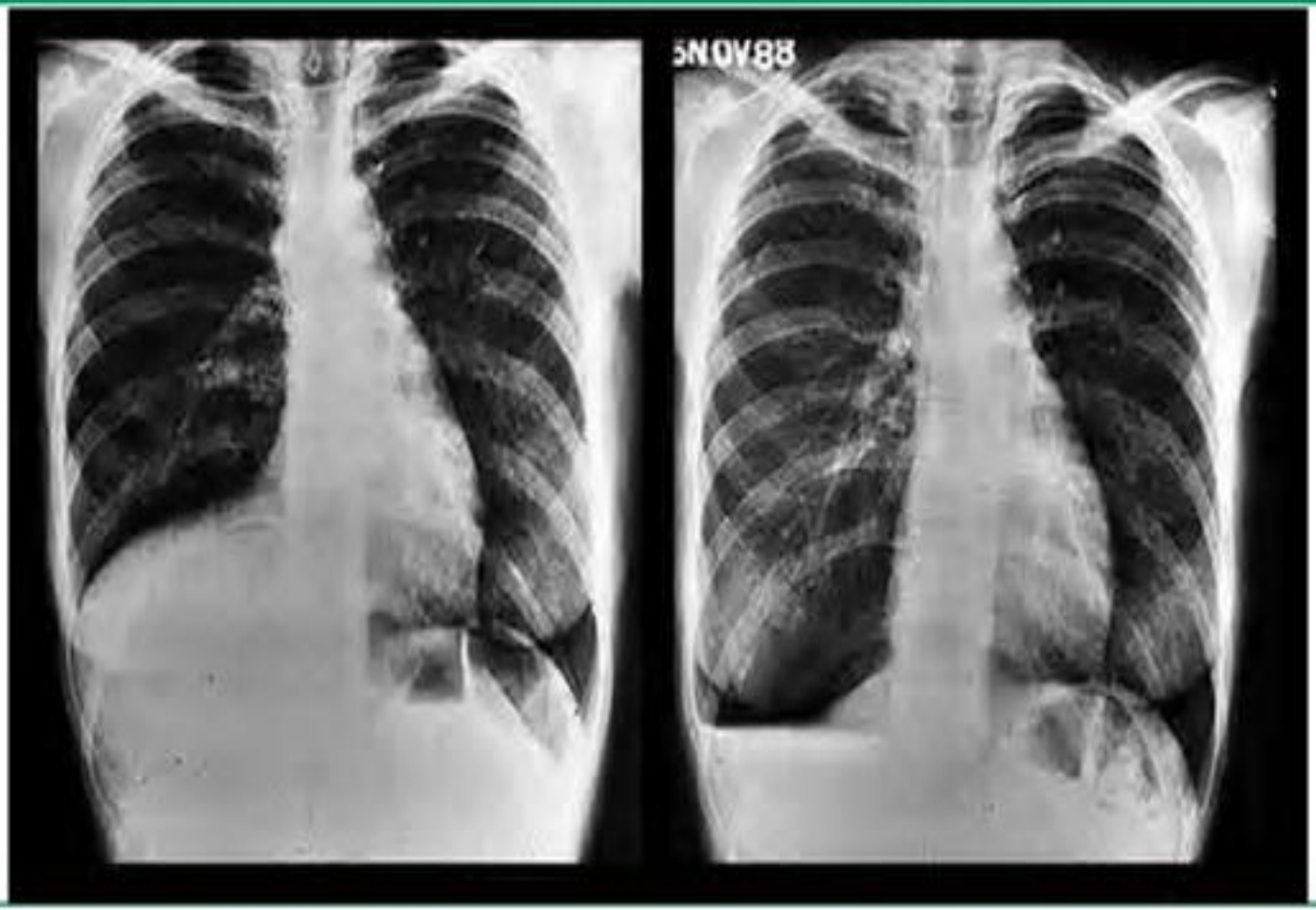

Left panel: Right subpulmonic pleural effusion in patient after mediastinal irradiation. The right lung base is elevated as well as the right hilum. Right panel: After thoracentesis, a residual hydropneumothorax with a large right sided gas-liquid level ensues, thus proving that the elevation of the right lung base was not due to an elevated right hemidiaphragm but to a subpulmonic pleural effusion.

Hepatic hydrothorax

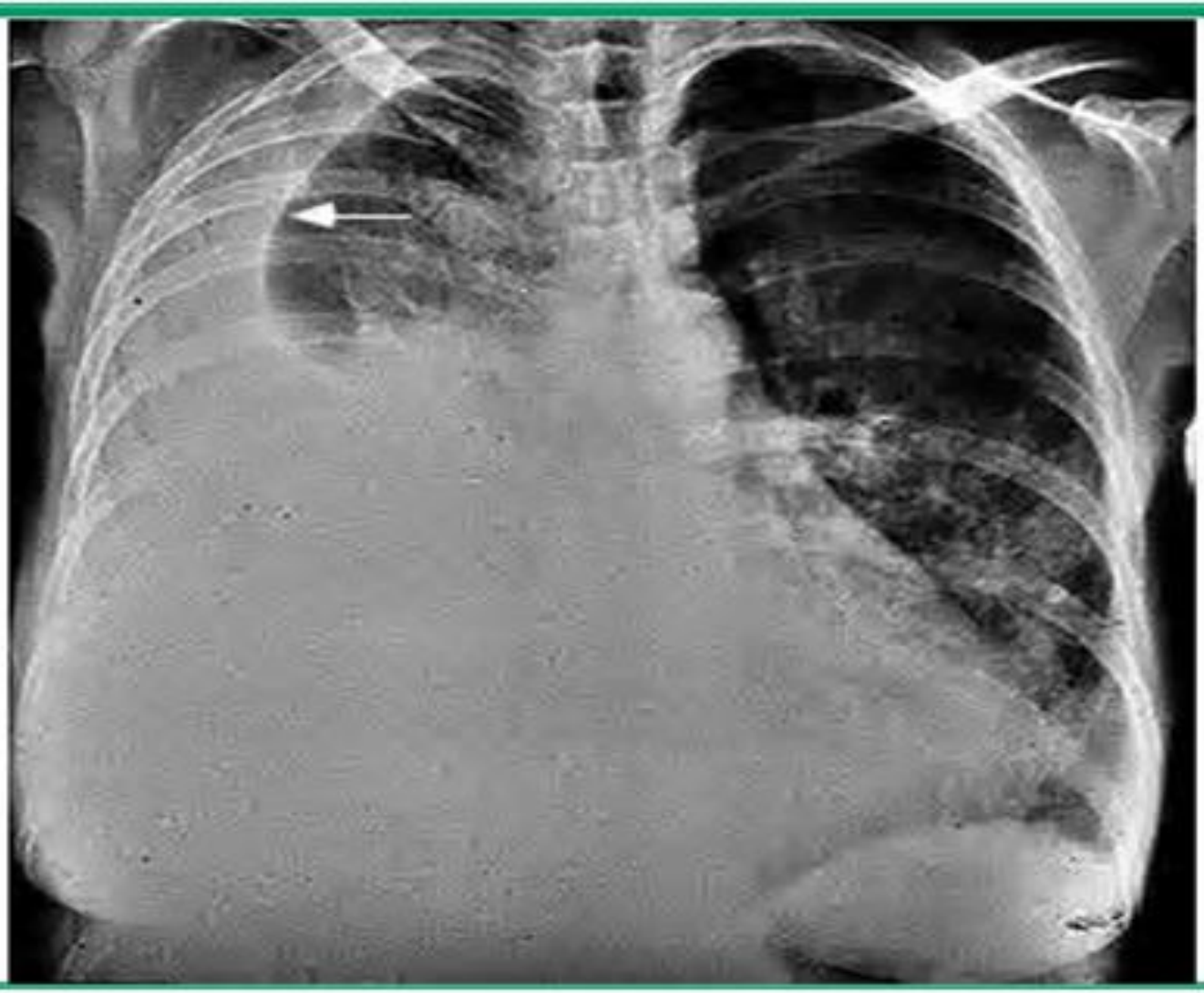

Large right sided pleural effusion forming typical meniscoid arc (arrow) in patient with advanced liver cirrhosis.

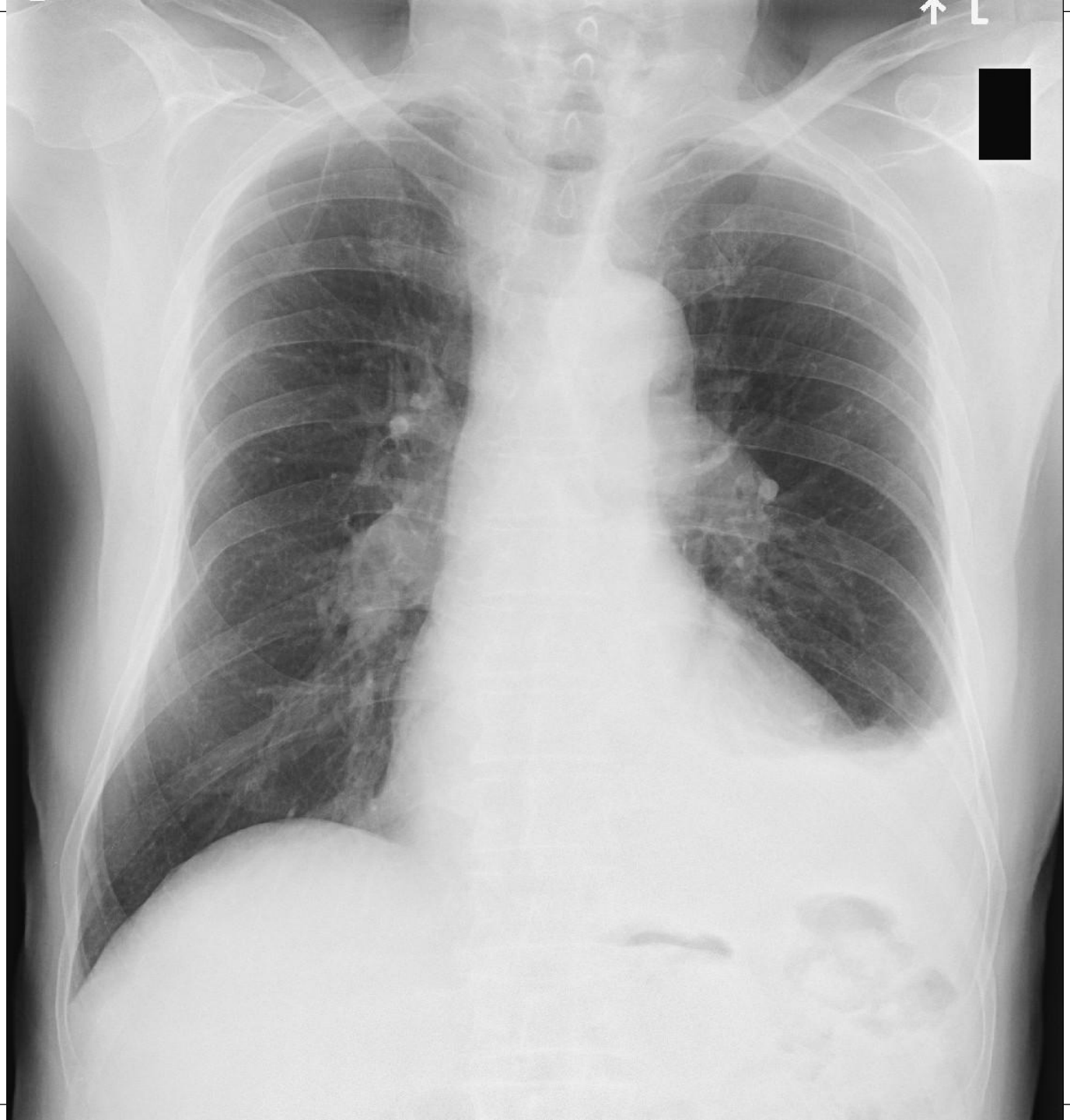
L

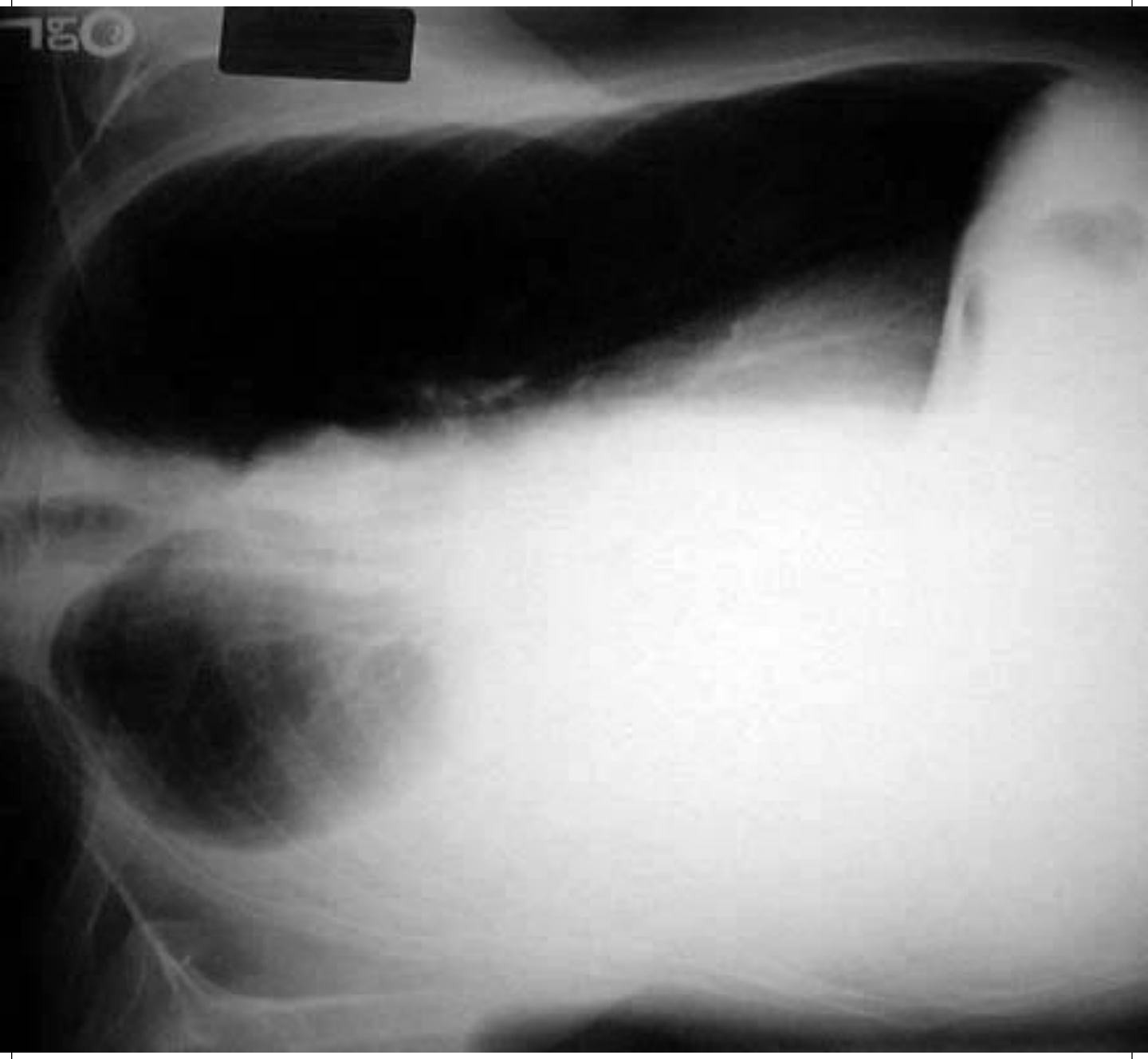

Primary tuberculosis in infant

Large left sided pleural effusion produces complete opacification of the left hemithorax with cardiomediastinal shift to the right.

Primary tuberculosis in pregnant woman

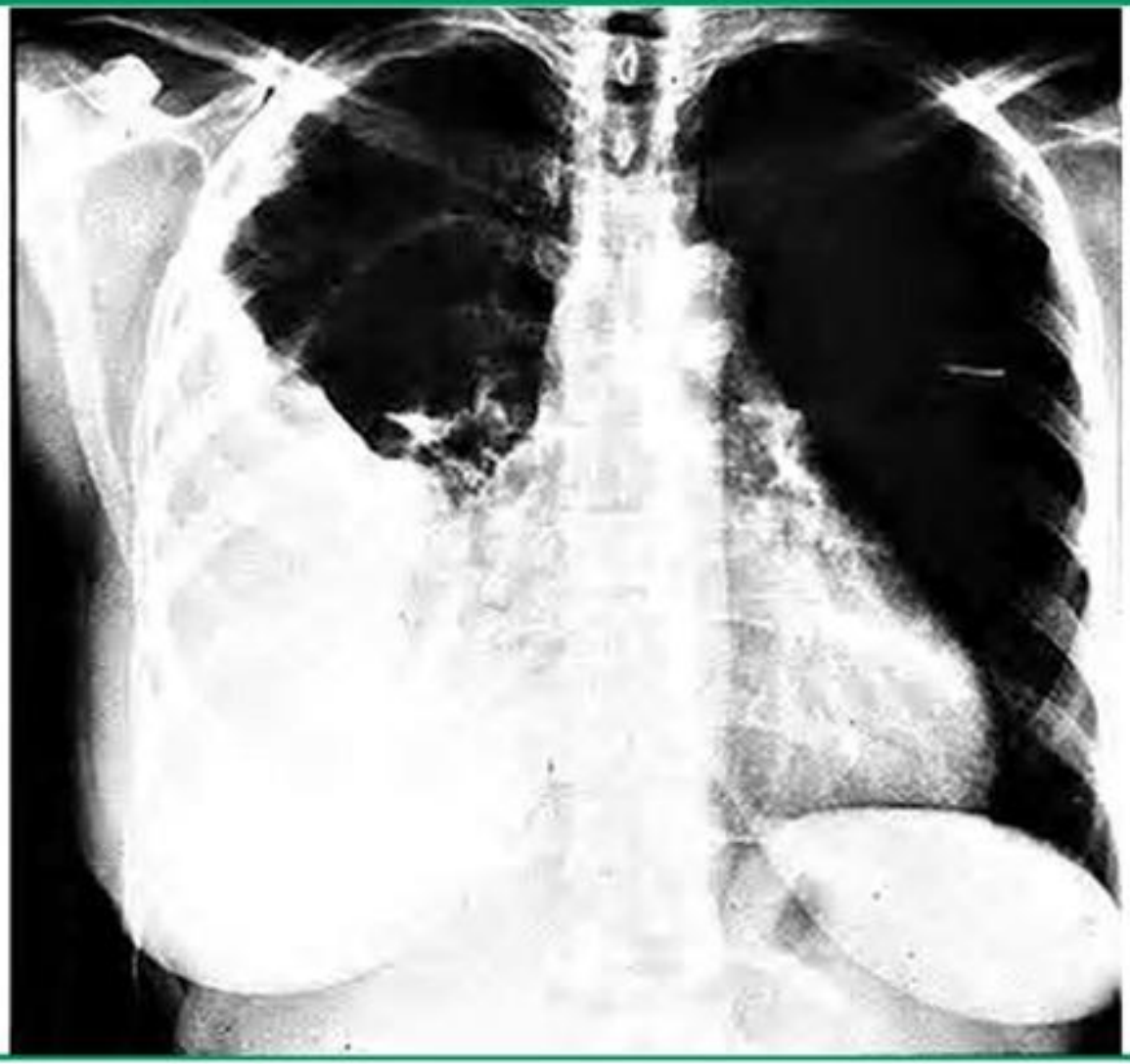

Large right sided pleural effusion with typical meniscoid arc and with extension into the major fissure.

Malignant pleural effusions

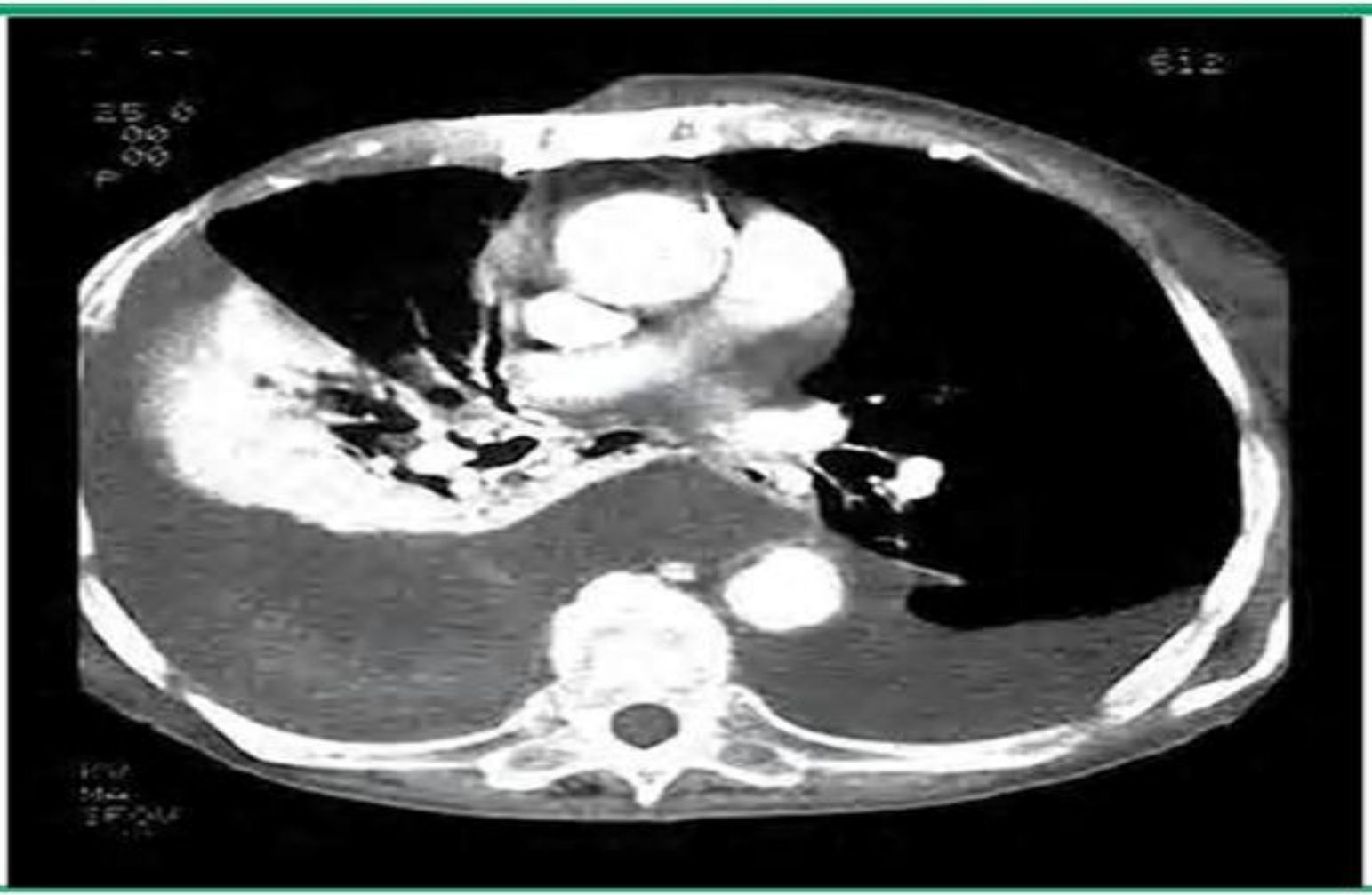

Bilateral malignant pleural effusions in patient with metastatic carcinoma of the breast. CT scan shows bilateral posterior pleural effusions and passive atelectasis of the right lower lobe with marked enhancement after intravenous contrast material injection.

Empyema

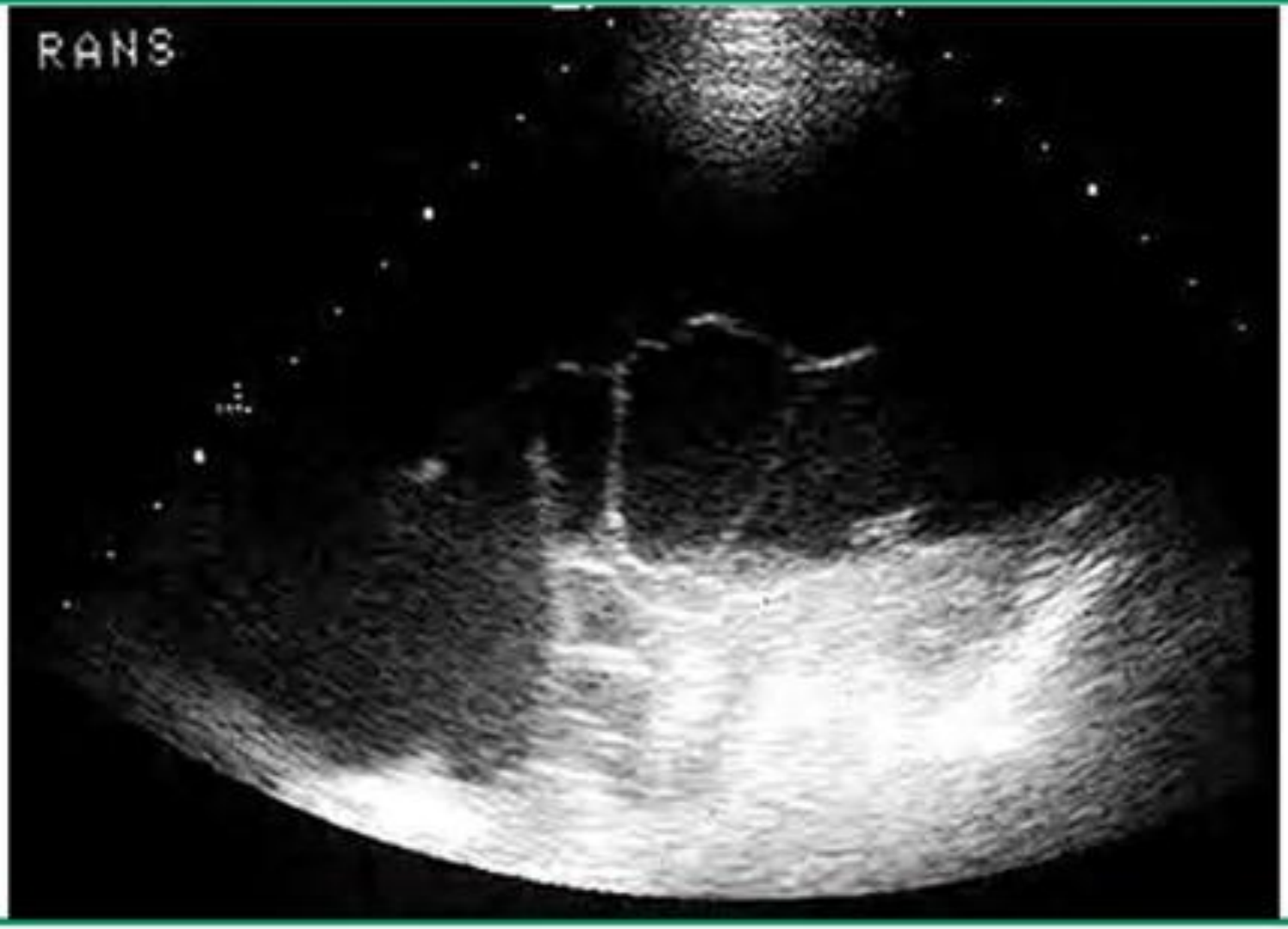

Empyema with multiple septations demonstrated on an ultrasonogram of the lower left hemithorax.

Transverse ultrasound image shows right-sided pleural effusion (*arrowhead). The diaphragm can be visualized as a* hyperechoic line separating the right lung base from the liver

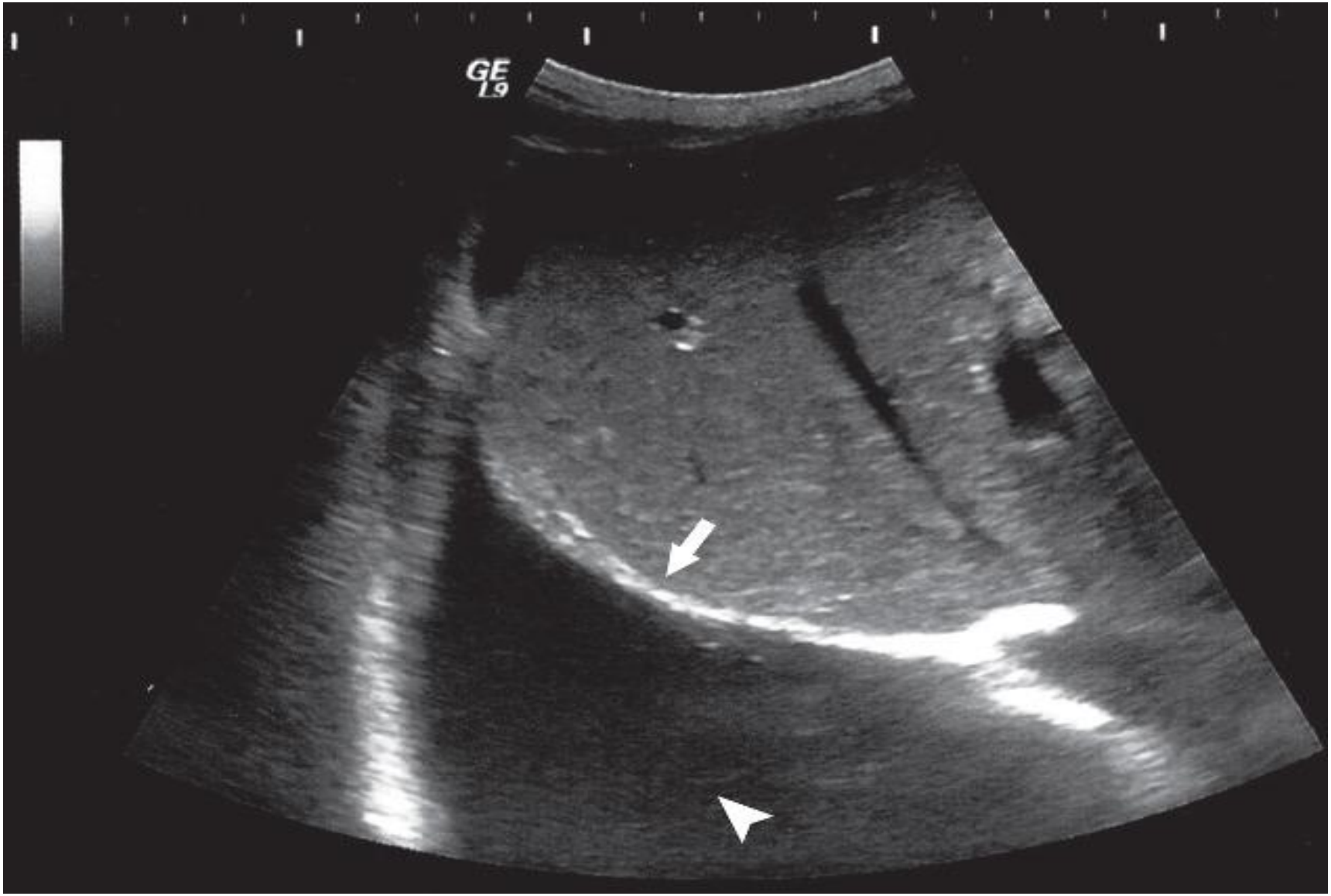

Imaging
التصوير الشعاعي

- trapped (loculated) by pleural adhesions → unusual collections along the lateral chest wall or within lung fissures
- Pseudotumors : Round or oval fluid collections in fissures
- Massive pleural effusion : caused by cancer but may be seen in tuberculosis

Loculated pleural effusion

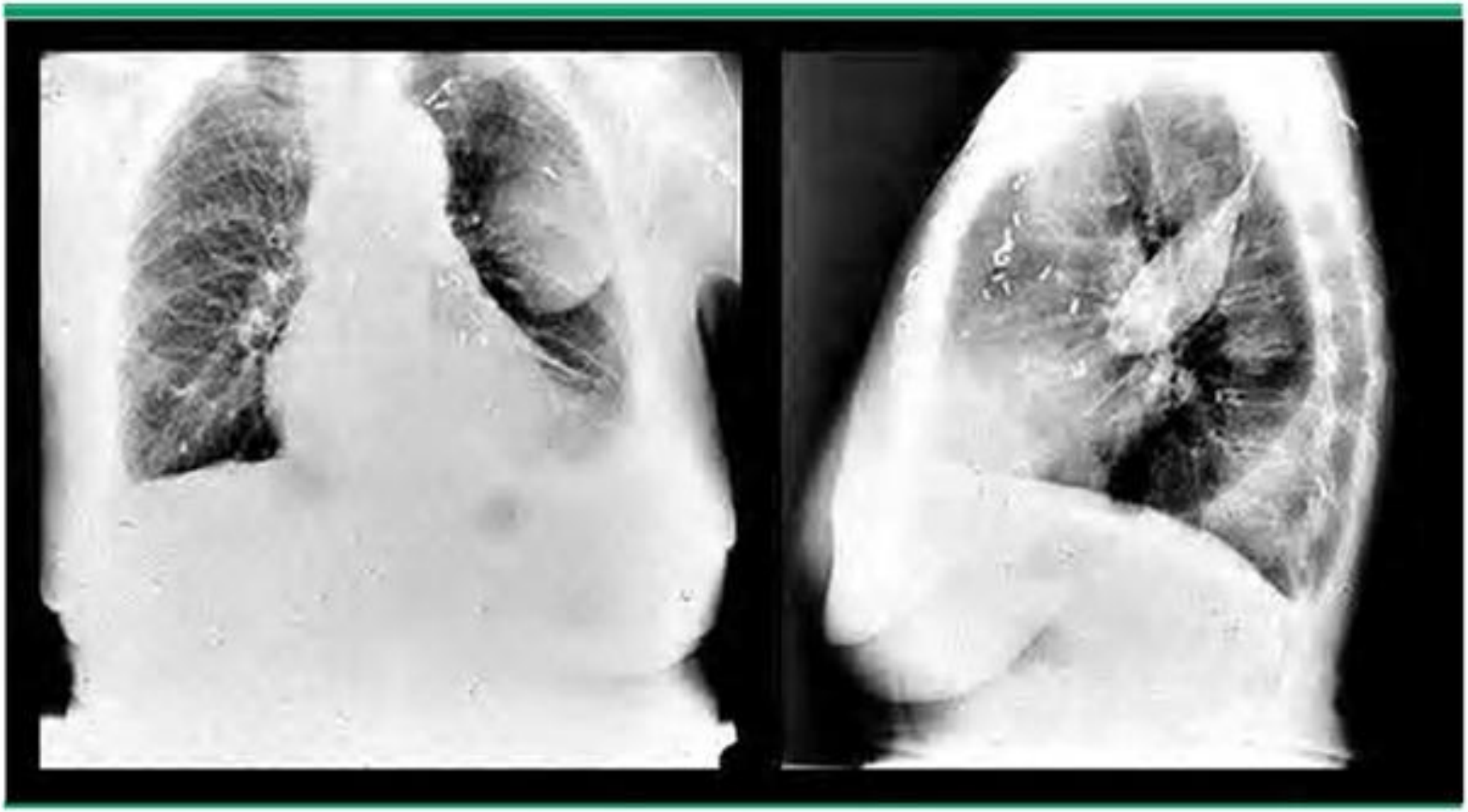

Chest radiographs show a loculated pleural effusion in the left major fissure. The mass-like appearance on the PA view (left) forms a pseudotumor. The lateral view (right) clearly localizes the mass to the major fissure.

Posteroanterior (a) and lateral (b) chest radiographs show right-sided encysted pleural effusion

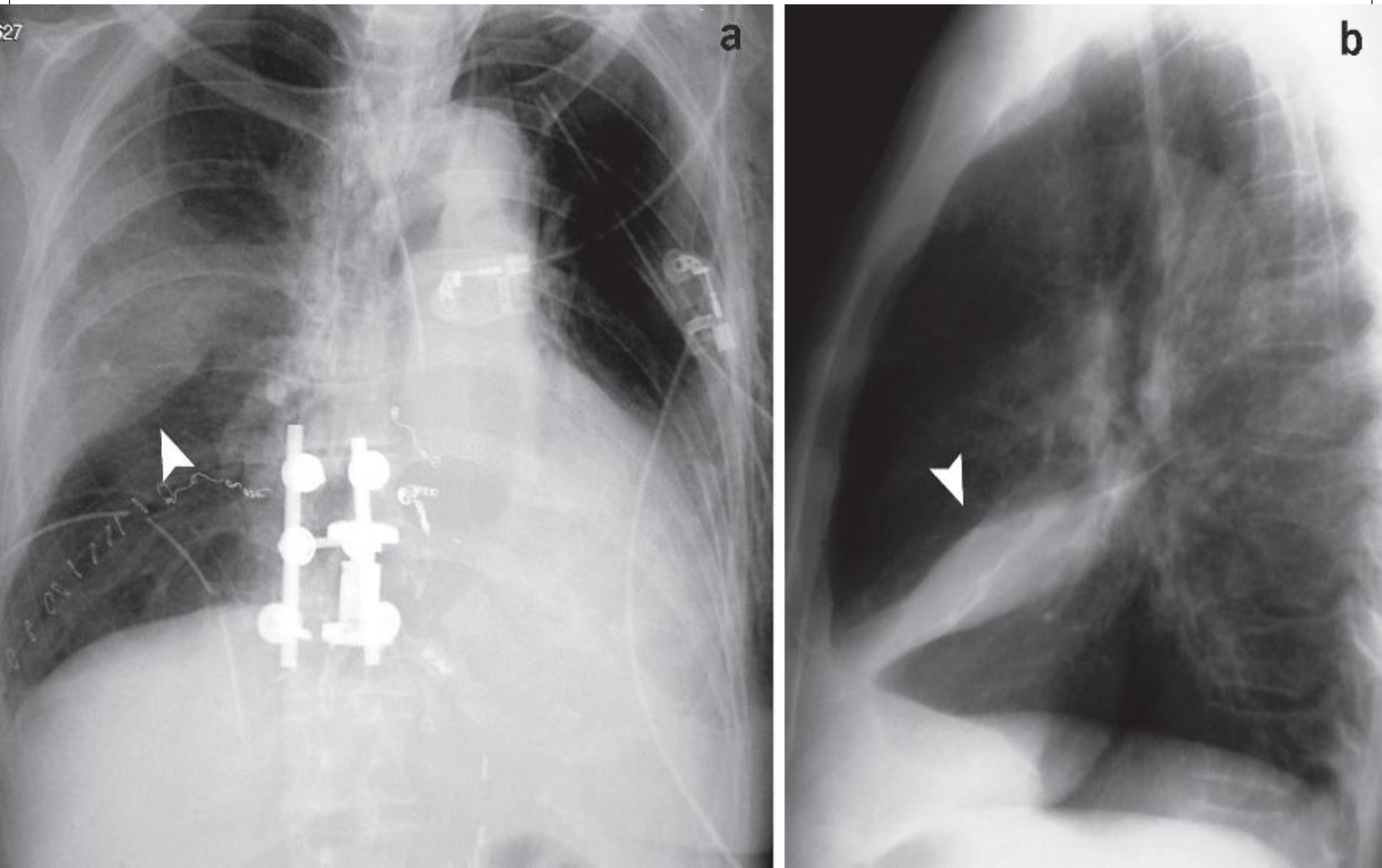

Loculated pleural hematoma

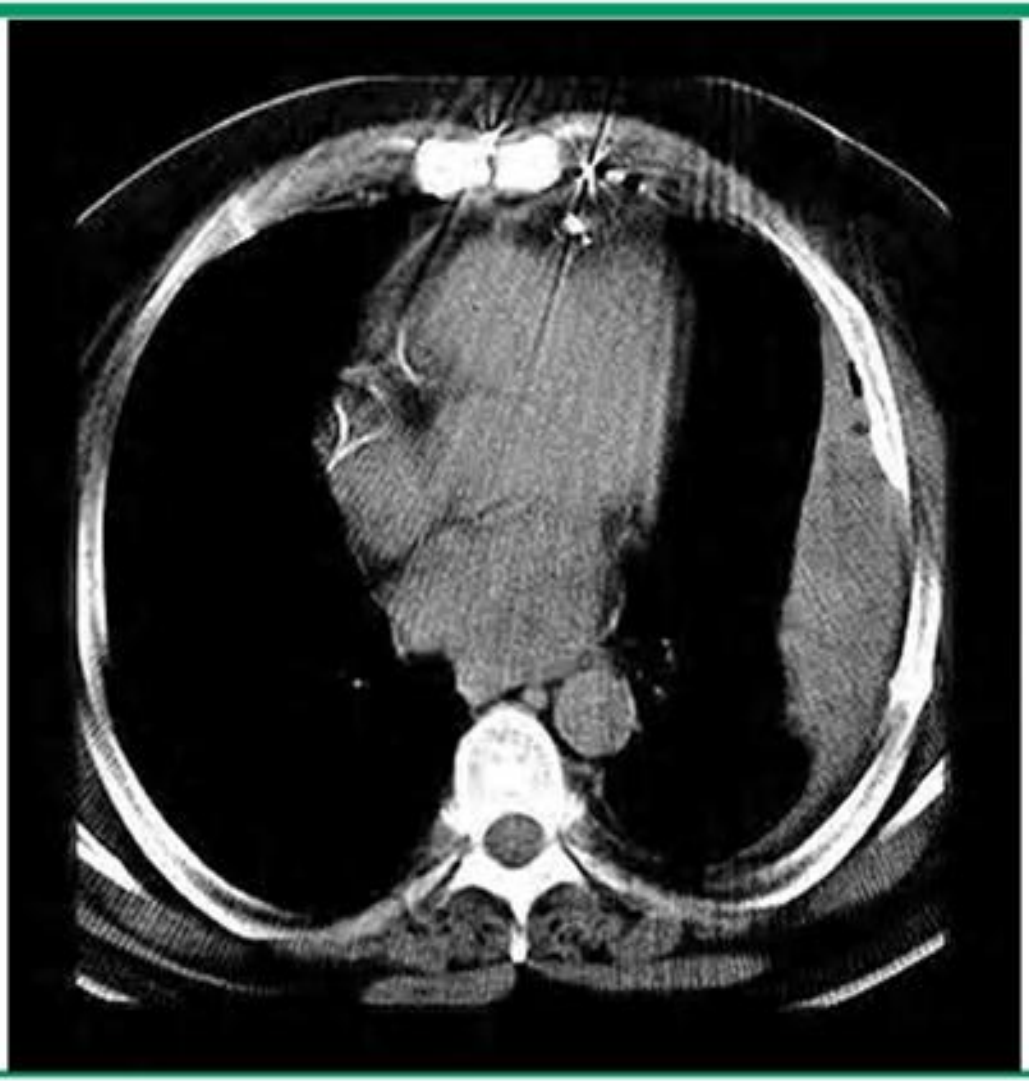

Loculated pleural hematoma in left hemithorax after CABG. The loculated collection of blood has higher attenuation than the chest wall musculature.

Empyema with calcifications

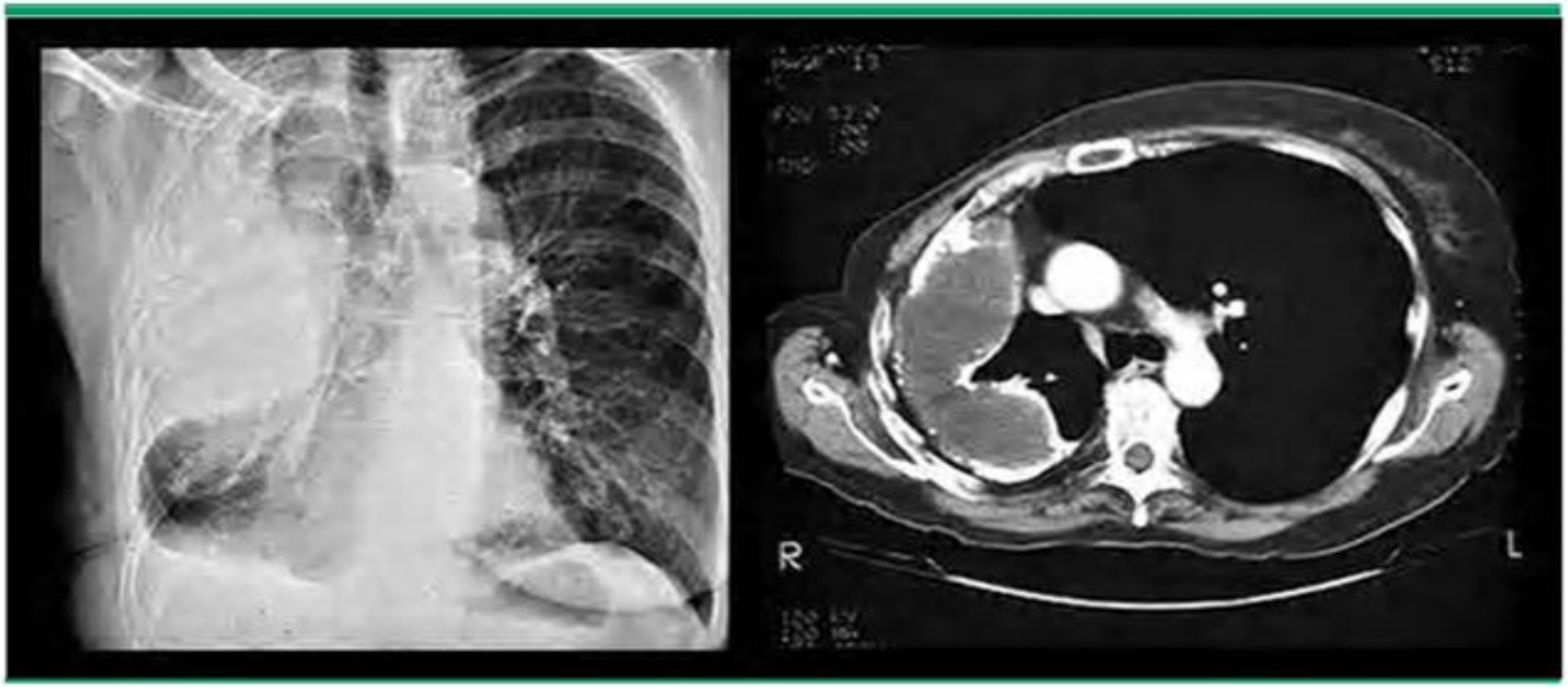

Empyema due to previous pneumothorax therapy for cavitary tuberculosis. Left: Chest radiograph shows large right sided pleural mass with a sharp border towards the lung and obtuse angles of interface towards the chest wall. Slight caudad "drooping" is visible. Pleural calcifications are present. The lateral costophrenic sulcus is obscured. Right: CT scan shows a large loculated collection of liquid in the right hemithorax with obvious calcifications of the visceral and parietal pleura. Restrictive changes are evident and account for the small size of the right hemithorax. The thickness of the extrapleural fat in the posterolateral aspect of the right hemithorax is increased when compared to the left side. This compensates for the low lung volume on the right side.

Empyema with split pleura sign

CT scan demonstrates a loculated collection of pleural effusion in the left hemithorax with enhancing visceral and parietal pleura ("split pleura" sign) and a few bubbles of gas within the empyema, likely due to a gas forming organism. Larger collections of gas are usually indicative of a bronchopleural fistula. The contralateral right transudative effusion does not show enhancement of the pleura after intravenous contrast material administration.

Treatment
التدبير العلاجي

- **Transudative Pleural Effusion :**

  *** directed at the underlying condition.**
  *** Therapeutic thoracentesis for severe dyspnea**

Malignant Pleural Effusion

- **Between 40% and 80% of exudative pleural effusions are malignant**
- **over 90% of malignant pleural effusions are exudative.**
- **Mechanism :**

  - direct tumor involvement of the pleura

  - local inflammation in response to tumor spread

  -impairment or disruption of lymphatics.

  - Increased pleural membrane and capillary permeability.

Malignant Pleural Effusion

- Neoplastic :
  - lung carcinoma (35%)
  - lymphoma (10%)
  - metastases: breast (25%), ovary, kidney
  - mesothelioma
- Dyspnea occurs in over half of patients
- Hypoxemia from intrapulmonary shunting and V/Q mismatching is common

Malignant pleural effusions

Bilateral malignant pleural effusions in patient with carcinoma of the breast and bilateral mastectomies. CT scan shows a free right pleural effusion and two left-sided collections of pleural liquid, loculated medially and anterolaterally.

Treatment of Malignant Pleural Effusion

- therapy for the underlying malignancy
- drainage through repeated thoracentesis or placement of a chest tube.
- Pleurodesis :
  an irritant(doxycycline 500 mg in 50–100 mL saline) and sterile, asbestos-free talc (by poudrage at thoracoscopy) is placed into the pleural space following chest tube drainage → (form fibrous adhesions between the visceral and parietal pleura)
- success rate : Doxycycline → 70–75%
  talc → 90%

Parapneumonic Pleural Effusion

- exudates
- accompany approximately 40% of bacterial pneumonias.
- three categories: simple or uncomplicated, complicated, and empyema.
- simple effusions :
  - * sterile exudates of modest size that resolve quickly with antibiotic treatment of pneumonia.
  - * They do not need drainage

Parapneumonic Pleural Effusion

- **Empyema :**

  *** gross infection of the pleural space**

  *** positive Gram stain or culture.**

  *** Empyema should always be drained by tube thoracostomy**

- **Complicated parapneumonic effusions :**

  *** low glucose level, low pH, or evidence of loculation**

  *** larger than simple parapneumonic effusions**

  *** form a fibropurulent pleural trapping → permanent impairment**

تقيح الجنب

- > 40 % من المصابين بذات الرئة المكتسبة بالمجتمع لديهم انصباب جنب & 15 % منهم يحدث لديهم تقيح جنب
- ارتفاع حرارة رغم الصادات ، أو غير عرضي
- العلاج : تفجير & صادات (4 أسابيع)

Bilateral empyema due to staphylococcus aureus

CT scan shows bilateral loculations of effusion with adjacent consolidated or compressed lung.

Pseudomonas empyema

Large left sided empyema due to Pseudomonas aeruginosa. Posterior collection of pleural effusion compresses the left lung and displaces the cardiomediastinal silhouette to the right.

Indication of Tube thoracostomy
استطبابات تفجير الجنب

- glucose is < 60 mg/dL
- the pH is < 7.2

- pH is between 7.2 and 7.3 or the LDH is > 1000 units/mL.

Hemothorax
الانصباب الدموي

- **A small-volume hemothorax : close observation.**
- **treated by immediate insertion of a large-bore thoracostomy tube to**

  (1) drain existing blood and clot
  (2) quantify the amount of bleeding
  (3) reduce the risk of fibrothorax
  (4) permit apposition of the pleural surfaces in an attempt to reduce hemorrhage.

Large pleural hematoma after trauma

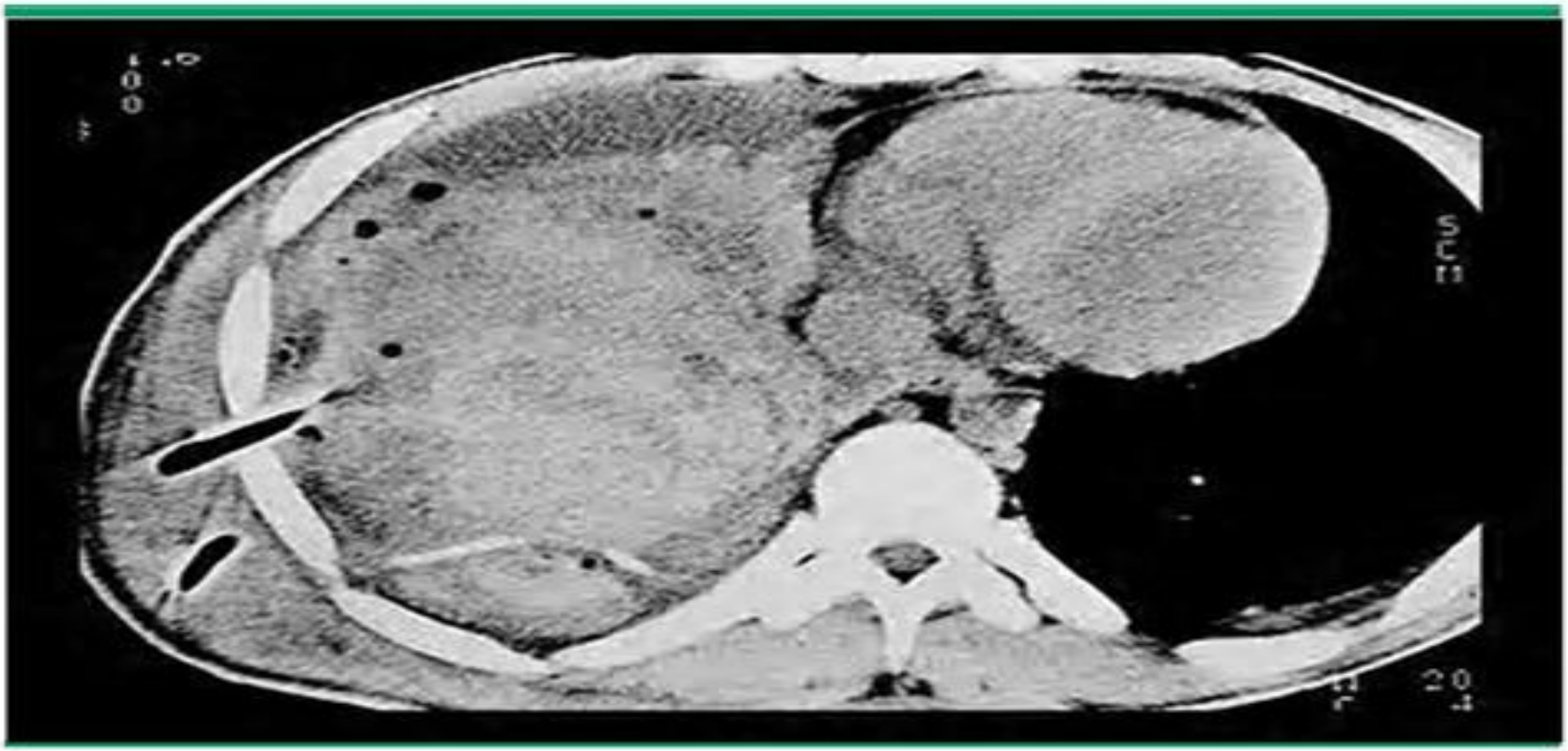

CT scan performed without intravenous injection of contrast material shows inhomogeneous opacification of the right hemithorax with mostly higher attenuation material. A right-sided chest tube is in place. Cardiomediastinal shift to the left is seen. The interventricular cardiac septum is seen as a higher attenuation structure when compared to the interventricular blood. This suggests a severe dilutional anemia due to severe hemorrhage with a hemoglobin level of less than 7 g/dL.

leural hematoma in right hemithorax

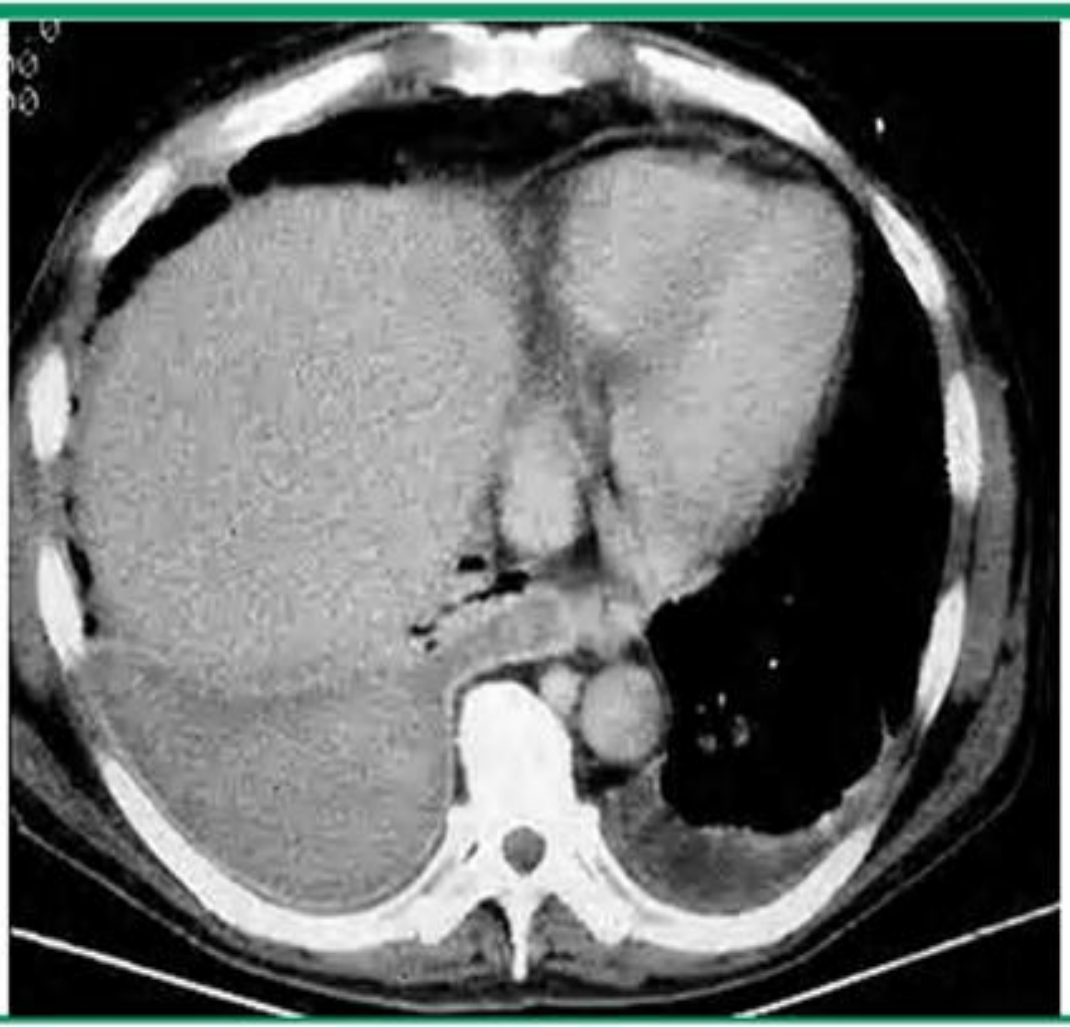

Spontaneous hemorrhage in an anticoagulated patient. The right effusion has high attenuation due to the fresh blood. The left pleural effusion is transudative and has lower attenuation.

انصباب الجنب الدرني

- أول تظاهر للإنتان الدرني الأولي
- انصباب التدرن الثانوي (انفتاح كهف على الجنب) ← تقيح جنب درني
- حمى ، ألم جنبي ، انصباب دون إصابة رئوية (أولي) ، أو غير عرضي
- السائل : أصفر ليموني ، نتحي على حساب العدلات و بعد أسبوع على حساب اللمفاويات
- التشخيص : تحري كوخ ، خزعة جنب
- التطور : شفاء عفوي ، تدرن دخني ، كثافة جنبية

Pleural effusion: main causes and features

Cause	Appearance of fluid	Type of fluid	Predominant cells in fluid	Other diagnostic features
Tuberculosis	Serous, usually amber-coloured	Exudate	Lymphocytes (occasionally polymorphs)	Positive tuberculin test Isolation of *M. tuberculosis* from pleural fluid (20%)
				Positive pleural biopsy (80%)
Malignant disease	Serous, often blood-stained	Exudate	Serosal cells and lymphocytes	Positive pleural biopsy (40%) Evidence of malignant disease elsewhere
			Often clumps of malignant cells	
Cardiac failure	Serous, straw-coloured	Transudate	Few serosal cells	Other evidence of left ventricular failure Response to diuretics
Pulmonary infarction	Serous or blood-stained	Exudate (rarely transudate)	Red blood cells Eosinophils	Evidence of pulmonary infarction Source of embolism
				Factors predisposing to venous thrombosis
Rheumatoid disease	Serous Turbid if chronic	Exudate	Lymphocytes (occasionally polymorphs)	Rheumatoid arthritis; rheumatoid factor and anti-CCP antibodies
				Cholesterol in chronic effusion; very low glucose in pleural fluid
SLE	Serous	Exudate	Lymphocytes and serosal cells	Other manifestations of SLE Antinuclear factor or anti-DNA in serum
Acute pancreatitis	Serous or blood-stained	Exudate	No cells predominate	High amylase in pleural fluid (greater than in serum)
Obstruction of thoracic duct	Milky	Chyle	None	Chylomicrons